

**AMERICAN ASSOCIATION OF CLINICAL ENDOCRINOLOGISTS,
ASSOCIAZIONE MEDICI ENDOCRINOLOGI, AND EUROPEAN THYROID
ASSOCIATION MEDICAL GUIDELINES FOR CLINICAL PRACTICE FOR
THE DIAGNOSIS AND MANAGEMENT OF THYROID NODULES**

*Hossein Gharib, MD, MACP, MACE;
Enrico Papini, MD, FACE;
Ralf Paschke, MD;
Daniel S. Duick, MD, FACP, FACE;
Roberto Valcavi, MD, FACE;
Laszlo Hegedüs, MD;
Paolo Vitti, MD;
for the AACE/AME/ETA Task Force on Thyroid Nodules**

American Association of Clinical Endocrinologists, Associazione Medici Endocrinologi, and European Thyroid Association Medical Guidelines for Clinical Practice for the Diagnosis and Management of Thyroid Nodules are systematically developed statements to assist health care professionals in medical decision making for specific clinical conditions. Most of the content herein is based on literature reviews. In areas of uncertainty, professional judgment was applied.

These guidelines are a working document that reflects the state of the field at the time of publication. Because rapid changes in this area are expected, periodic revisions are inevitable. We encourage medical professionals to use this information in conjunction with their best clinical judgment. Any decision by practitioners to apply these guidelines must be made in light of local resources and individual patient circumstances.

*Task Force Committee Members are listed on the second page and in the Acknowledgment.

© 2010 AACE.

These guidelines are based on *Endocr Pract.* 2006 Jan-Feb;12(1):63-102. Used with permission.



WRITING COMMITTEE

Primary Authors

*Hossein Gharib, MD, MACP, MACE**

*Enrico Papini, MD, FACE**

*Ralf Paschke, MD**

Daniel S. Duick, MD, FACP, FACE

Roberto Valcavi, MD, FACE

Laszlo Hegedüs, MD

Paolo Vitti, MD

AACE/AME/ETA TASK FORCE COMMITTEE MEMBERS

Sofia Tseleni Balafouta, MD

Zubair Baloch, MD

Anna Crescenzi, MD

Henning Dralle, MD

Roland Gärtner, MD

Rinaldo Guglielmi, MD

Jeffrey I. Mechanick, MD, FACP, FACN, FACE

Christoph Reiners, MD

Istvan Szabolcs, MD, PhD, DSc

Martha A. Zeiger, MD, FACS

Michele Zini, MD

*Cochairpersons.

Abbreviations:

AACE = American Association of Clinical Endocrinologists; **AFTN** = autonomously functioning thyroid nodule; **AME** = Associazione Medici Endocrinologi; **BEL** = best evidence level; **CNB** = core-needle biopsy; **CT** = computed tomography; **EL** = evidence level; **ETA** = European Thyroid Association; **FNA** = fine-needle aspiration, **LNB** = large-needle biopsy; **MEN 2** = multiple endocrine neoplasia type 2; **MeSH** = Medical Subject Headings; **MNG** = multinodular goiter; **MRI** = magnetic resonance imaging; **MTC** = medullary thyroid carcinoma; **PEI** = percutaneous ethanol injection; **PLA** = percutaneous laser ablation; **PTC** = papillary thyroid carcinoma; **RFA** = radiofrequency ablation; **rhTSH** = recombinant human TSH; **TPOAb** = anti-thyroid peroxidase antibody; **TRAb** = anti-TSH-receptor antibody; **TSH** = thyrotropin (thyroid-stimulating hormone); **UGFNA** = US-guided FNA; **US** = ultrasonography, ultrasonographic

INTRODUCTION

This document was prepared as a collaborative effort between the American Association of Clinical Endocrinologists (AACE), the Associazione Medici Endocrinologi (Italian Association of Clinical Endocrinologists) (AME), and the European Thyroid Association (ETA). This guideline covers diagnostic and therapeutic aspects of thyroid nodular disease but not thyroid cancer management.

The AACE protocol for standardized production of clinical practice guidelines was followed to rate the evidence level of each reference (on a scale of 1 to 4) and to link the guidelines to the strength of recommendations on the basis of grade designations A (action based on strong evidence) through D (action not based on any evidence or not recommended). The best evidence level (BEL), corresponding to the best conclusive evidence found, accompanies the recommendation grade. All recommendations resulted from a consensus among the AACE, AME, and ETA primary writers and were influenced by input from the Task Force members and reviewers. Some recommendations were upgraded or downgraded on the basis of expert opinion. In these cases, subjective factors such as clinical experience, cost, risks, and regional availability of specific technologies and expertise took priority over the reported BEL.

The use of high-resolution ultrasonography (US), sensitive thyrotropin (TSH) assay, and fine-needle aspiration (FNA) biopsy is the basis for management of thyroid nodules. Thyroid scintigraphy is not necessary for diagnosis in most cases. However, it may be warranted in patients

with a low serum TSH value or a multinodular gland to detect functional autonomy, most common in iodine-deficient areas. Measurement of serum TSH is the best initial laboratory test of thyroid function and should be followed by measurement of free thyroxine and triiodothyronine if the TSH value is decreased, and measurement of anti-thyroid peroxidase antibodies (TPOAb) if the TSH value is above the reference range. A single, nonstimulated calcitonin measurement can be used in the initial workup of thyroid nodules and is recommended before thyroid nodule surgery.

Although thyroid nodules are a common incidental finding, US should not be performed as a screening test. Most patients with thyroid nodules are asymptomatic, but the absence of symptoms does not rule out malignancy; thus, clinical and US risk factors for malignant disease should always be reviewed. All patients with a palpable thyroid nodule or with clinical risk factors should undergo US examination.

Thyroid FNA biopsy is best performed under US guidance because of the increase in diagnostic accuracy of the procedure. US-guided FNA (UGFNA) biopsy is recommended for nodules smaller than 10 mm if clinical information or US features are suspicious. Cytologic smears or liquid-based cytology should be interpreted by a pathologist with specific experience. A classification scheme in 5 cytologic diagnostic categories is recommended for the cytologic report: nondiagnostic, benign, follicular lesion, suspicious, or malignant. Currently, no single cytochemical or genetic marker is specific and sensitive enough to replace the morphologic diagnosis of follicular lesion or suspicious for neoplasm. However, use of these markers may be considered in selected cases. Hormone determination on washout from FNA biopsy may increase the diagnostic accuracy of FNA biopsy in suspicious node metastasis or hyperplastic parathyroid glands. US-guided core-needle biopsy should be reserved for patients with neck masses and uncertain FNA biopsy diagnosis.

Patients with benign thyroid nodules should undergo clinical and US follow-up. Symptomatic goiters, whether euthyroid or hyperthyroid, may be treated surgically or with radioiodine. Although we do not recommend routine levothyroxine suppressive therapy, it may be considered for small nodular goiters in young patients living in iodine-deficient regions. Percutaneous ethanol injection is useful in the treatment of benign cystic thyroid lesions. Symptomatic patients with benign nodules who decline surgery or who are at surgical risk may benefit from US-guided thermal ablation.

Malignant or suspicious nodules should be treated surgically. Preoperative evaluation with US and UGFNA biopsy is recommended for appropriate surgical planning.

Suggestions for thyroid nodule management during pregnancy and childhood are also presented.

1. THYROID NODULES: THE SCOPE OF THE PROBLEM

Thyroid nodules are a common clinical finding, with an estimated prevalence on the basis of palpation that ranges from 3% to 7% (1,2). The prevalence of clinically inapparent thyroid nodules is estimated with US at 20% to 76% in the general population, with a prevalence similar to that reported from autopsy data (3-5). Moreover, 20% to 48% of patients with 1 palpable thyroid nodule are found to have additional nodules on US investigation (5,6). Thyroid nodules are more common in elderly persons, in women, in those with iodine deficiency, and in those with a history of radiation exposure. The estimated annual incidence rate of 0.1% in the United States suggests that 300 000 new nodules are detected in this country every year (7,8).

This guideline covers diagnostic and therapeutic aspects of thyroid nodular disease but does not cover thyroid cancer management.

2. CLINICAL EVALUATION AND DIAGNOSIS

2.1. History and Physical Examination

Both benign and malignant disorders can cause thyroid nodules (Box 1) (9). Hence, the clinical importance of newly diagnosed thyroid nodules is primarily the exclusion of malignant thyroid lesions (6,10) (Box 2). In iodine-deficient areas, however, local symptoms, functional autonomy, and hyperthyroidism are common clinical problems (11).

2.1.1. History

During examination, patients should be asked about a family history of benign or malignant thyroid disease.

Familial medullary thyroid carcinoma (MTC), multiple endocrine neoplasia type 2 (MEN 2), familial papillary thyroid tumors, familial polyposis coli, Cowden disease, and Gardner syndrome should be considered (12-14).

Previous disease or treatments involving the neck (head and neck irradiation during childhood), recent pregnancy, and rapidity of onset and rate of growth of the neck swelling should be documented. Presence of thyroid nodules during childhood and adolescence should induce caution because the malignancy rate is 3- to 4-fold higher than in adult patients (15). The risk of thyroid cancer is also higher in older persons and in men (3,9).

2.1.2. Symptoms and Signs

Most patients with thyroid nodules have few or no symptoms, and usually no clear relationship exists between nodule histologic features and the reported symptoms. Thyroid nodules are often discovered incidentally on physical examination, color Doppler evaluation of the carotid artery, or imaging studies performed for unrelated reasons (16).

In symptomatic patients, a detailed history and a complete physical examination may guide the selection of appropriate clinical and laboratory investigations. Slow but progressive growth of the nodule (during weeks or months) is suggestive of malignant involvement.

Sudden pain is commonly due to hemorrhage in a cystic nodule. In patients with progressive and painful enlargement of a thyroid nodule, however, anaplastic carcinoma or primary lymphoma of the thyroid should be considered (17). Symptoms such as a choking sensation, cervical tenderness or pain, dysphagia, or hoarseness may be perceived as attributable to thyroid disease, but in most patients, these symptoms are caused by nonthyroid disorders. Slow-onset cervical symptoms and signs caused by the compression of vital structures of the neck or upper thoracic cavity usually occur if thyroid nodules are embedded within large goiters. When observed in the absence of a multinodular goiter (MNG), the symptoms of tracheal compression (cough and dysphonia) suggest an underlying malignant lesion. Surgical treatment should be considered in patients with growth of a thyroid mass and vocal cord paresis even if cytologic results are negative for malignancy (18,19). Differentiated thyroid carcinomas rarely cause airway obstruction, vocal cord paralysis, or esophageal symptoms at their clinical presentation. Hence, the absence of local symptoms does not rule out a malignant tumor (20).

Small differentiated thyroid cancers are frequently devoid of alarming characteristics on physical evaluation (21-23). However, a firm or hard, solitary or dominant thyroid nodule that clearly differs from the rest of the gland suggests an increased risk of malignant involvement (17). Therefore, despite the low predictive value of palpation (23,24), a careful inspection and palpation of the thyroid

Box 1 Causes of Thyroid Nodules

- Benign nodular goiter
- Chronic lymphocytic thyroiditis
- Simple or hemorrhagic cysts
- Follicular adenomas
- Subacute thyroiditis
- Papillary carcinoma
- Follicular carcinoma
- Hürthle cell carcinoma
- Poorly differentiated carcinoma
- Medullary carcinoma
- Anaplastic carcinoma
- Primary thyroid lymphoma
- Sarcoma, teratoma, and miscellaneous tumors
- Metastatic tumors

Box 2
Factors Suggesting Increased Risk of Malignant Potential

History of head and neck irradiation
 Family history of medullary thyroid carcinoma, multiple endocrine neoplasia type 2, or papillary thyroid carcinoma
 Age <14 or >70 years
 Male sex
 Growing nodule
 Firm or hard consistency
 Cervical adenopathy
 Fixed nodule
 Persistent dysphonia, dysphagia, or dyspnea

gland and the anterior and lateral nodal compartments of the neck should always be done (Box 2).

Suppressed or low levels of thyrotropin (thyroid-stimulating hormone; TSH) are associated with a decreased probability of malignancy (25), and autonomously functioning thyroid nodules (AFTNs) in adults need no further cytologic evaluation because the incidence of malignancy is exceedingly low (26). Hyperfunctioning MNGs, however, may harbor both hyperfunctioning areas and cold (potentially malignant) lesions (22). Nodules appearing in patients with Graves disease or Hashimoto thyroiditis should be managed in the same way as in any other patients (27).

2.2. Thyroid Incidentaloma

Thyroid lesions discovered on computed tomography (CT) or magnetic resonance imaging (MRI) performed for other reasons have an uncertain risk of malignancy and should undergo US evaluation before considering evaluation with FNA biopsy (28,29). Nodules are detected infrequently by ¹⁸F-fluorodeoxyglucose positron emission tomography, but when found have a high risk of malignancy (30,31). Such lesions should undergo focused US evaluation followed by FNA biopsy.

Focal lesions detected by technetium Tc 99m sestamibi scans have a high risk of malignancy (32) and should be evaluated by US.

2.3. Key Recommendations

2.3.1. History

- Record the following information (**Grade B; BEL 2**):
 - Age
 - Family history of thyroid disease or cancer
 - Previous head or neck irradiation
 - Rate of growth of the neck mass
 - Dysphonia, dysphagia, or dyspnea

- Symptoms of hyperthyroidism or hypothyroidism
- Use of iodine-containing drugs or supplements
- Most nodules are asymptomatic, and absence of symptoms does not rule out malignancy (**Grade C; BEL 3**)

2.3.2. Physical Examination

- A careful physical examination of the thyroid gland and cervical lymph nodes is mandatory (**Grade A; BEL 3**)
- Record (**Grade C; BEL 3**):
 - Location, consistency, and size of the nodule(s)
 - Neck tenderness or pain
 - Cervical adenopathy
- The risk of cancer is similar in patients with a solitary nodule or with MNG (**Grade B; BEL 2**)

3. US AND OTHER DIAGNOSTIC IMAGING STUDIES

3.1. When to Perform Thyroid US

High-resolution US is the most sensitive test available to detect thyroid lesions, measure their dimensions, identify their structure, and evaluate diffuse changes in the thyroid gland (33,34).

If results of palpation are normal, US should be performed when a thyroid disorder is suspected on clinical grounds or if risk factors have been recognized (Box 2). The physical finding of suspicious neck adenopathy warrants US examination of both lymph nodes and thyroid gland because of the risk of a metastatic lesion from an otherwise unrecognized papillary microcarcinoma (35).

In all patients with palpable thyroid nodules or MNGs, US should be performed to accomplish the following:

- Help with the diagnosis in difficult cases (as in chronic lymphocytic thyroiditis)

- Look for coincidental thyroid nodules or diffuse thyroid gland changes
- Detect US features suggestive of malignant growth and select the lesions to be recommended for FNA biopsy
- Choose the gauge and length of the biopsy needle
- Obtain an objective measure of the baseline volume of the thyroid gland and of lesions that will be assigned to follow-up or medical therapy

Standardized US reporting criteria should be followed, indicating position, shape, size, margins, content, and echogenic and vascular pattern of the nodule. Nodules with malignant potential should be carefully described.

3.2. US Criteria for FNA Biopsy of Palpable Nodules

The risk of cancer is not significantly higher for palpable solitary thyroid nodules than for multinodular glands or nodules embedded in diffuse goiters (22,23). Moreover, in 50% of thyroid glands with a “solitary” nodule on the basis of palpation, other small nodules are discovered by US (24). For MNGs, the cytologic sampling should be focused on lesions with suspicious US features rather than on larger or clinically dominant nodules (34,36).

US and color Doppler features have varying abilities to predict the risk of malignancy. The reported specificities for predicting malignancy are 41.4% to 92.2% for marked hypoechogenicity, 44.2% to 95.0% for microcalcifications (small, intranodular, punctate, hyperechoic spots with scanty or no posterior acoustic shadowing), 48.3% to 91.8% for irregular or microlobulated margins, and about 80% for chaotic arrangement or intranodular vascular images (37,38). The value of these features for predicting cancer is partially blunted by the low sensitivities, however, and no US sign independently is fully predictive of a malignant lesion (21). A rounded appearance or a “more tall (anteroposterior) than wide (transverse)” shape of the nodule is an additional US pattern suggestive of malignant potential (39,40). The coexistence of 2 or more suspicious US criteria greatly increases the risk of thyroid cancer (21,39-41).

Large neoplastic lesions may be characterized by degenerative changes and multiple fluid-filled areas, findings rarely noted in microcarcinomas. Although most complex thyroid nodules with a dominant fluid component are benign, UGFNA biopsy should always be performed because papillary thyroid carcinoma (PTC) can be partially cystic (42). Extension of irregular hypoechoic lesions beyond the thyroid capsule, invasion of prethyroid muscles, and infiltration of the recurrent laryngeal nerve are infrequent but threatening US findings that demand immediate cytologic assessment (34).

The presence of enlarged lymph nodes with no hilum, cystic changes, and microcalcifications is highly suspicious

(43,44). Rounded appearance and chaotic hypervascularity are more common but less specific findings (44). Such nodes and any coexistent thyroid nodules, whatever their size, always warrant UGFNA biopsy.

3.3. US Criteria for FNA Biopsy of Impalpable Nodules and Nodular Goiters

Clinically inapparent thyroid lesions were detected by US in about half of the women in several studies (2,8). The prevalence of cancer reported for nonpalpable thyroid lesions ranges from 5.4% to 7.7% (21,37,45) and appears to be similar to that reported for palpable lesions (5.0%-6.5%) (22,37,44-46). Clinical criteria for a malignant nodule are lacking for most nonpalpable lesions (20). Hence, it is essential to determine which thyroid lesions have a high malignant potential on the basis of their US features.

The US characteristics suggestive of malignant involvement in impalpable thyroid nodules are the same as in palpable nodules (21,38,40). The combination of nodule isoechoogenicity with a spongiform appearance, however, has a high predictive value for a benign lesion (38).

Malignant involvement is not less frequent in nodules smaller than 10 mm in diameter; thus, an arbitrary diameter cutoff for cancer risk is not justified (21) and suspicious lesions smaller than 10 mm should be assessed with FNA biopsy. Furthermore, early diagnosis and treatment of small tumors may be clinically important, but an aggressive disease course is rare in incidentally discovered microcarcinomas (47-49). Hence, incidental thyroid lesions with a diameter of about 5 mm should usually be followed up with US (48). A possible diagnostic algorithm for workup of thyroid nodules and the strength of indication for FNA biopsy are shown in Figures 1 and 2.

3.4. US Elastography

A thyroid nodule with firm or hard consistency is associated with an increased risk of malignancy. Elastography has recently been applied in the diagnostic approach to nodular thyroid disease and has shown a high sensitivity and specificity in selected patients. The predictive value of US-elastographic measurement seems to be independent of nodule size (50,51) and is maintained for lesions that are indeterminate on FNA biopsy (52).

Cystic nodules and nodules shown to have a calcified shell by US are not suitable for US-elastographic evaluation. Because the nodule to be examined must be clearly distinguishable from other nodules, MNGs with coalescent nodules are not suitable for this analysis (51). Larger prospective studies are needed to establish the diagnostic accuracy of this technique.

3.5. US Contrast Media

First- and second-generation contrast agents provide only ancillary data for the diagnosis of malignant thyroid

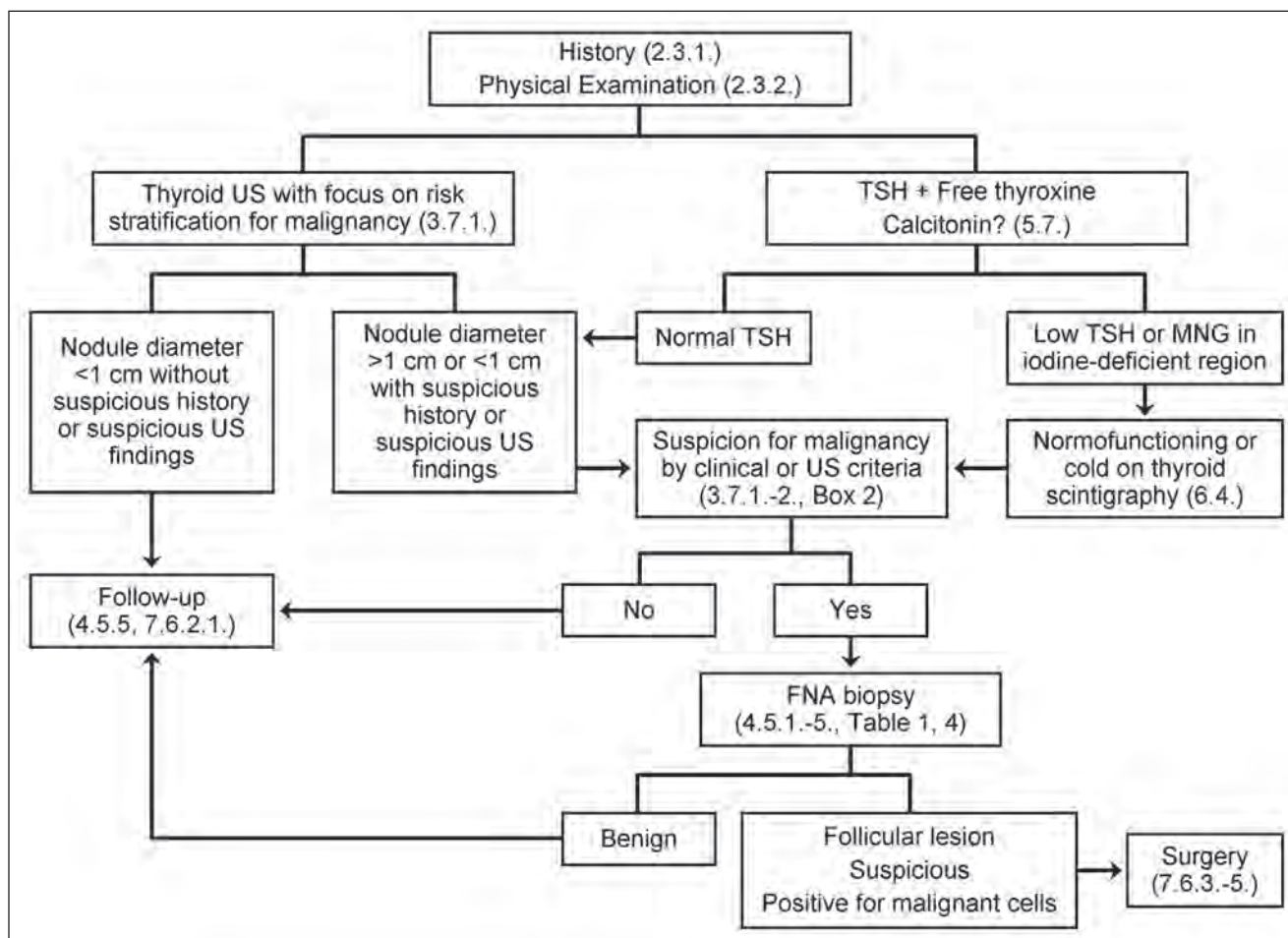


Fig 1. Flowchart indicating a scheme for the diagnosis and management of palpable thyroid nodules. Associated Key Recommendations shown in parentheses. FNA, fine-needle aspiration; MNG, multinodular goiter; TSH, thyrotropin; US, ultrasonography.

nodules and offer a modest improvement over the information obtainable with traditional color Doppler or power Doppler examinations (53,54). Currently, use of US contrast agents should be restricted to definition of the size and limits of necrotic zones after US-guided ablation procedures (54).

3.6. Other Imaging Techniques

MRI and CT should not be used routinely in nodular thyroid disease because they are rarely diagnostic for malignant lesions except in very advanced cases (28,29). MRI and CT may be of value, however, if assessment of size or substernal extension of a nodular goiter is desired for clinical management. CT contrast medium usually contains iodine (55), decreases subsequent uptake of radioiodine, and may also induce hyperthyroidism, especially in iodine-deficient geographic areas.

3.7. Key Recommendations

3.7.1. Ultrasonography

3.7.1.1. When to Perform Thyroid US

- US evaluation is not recommended as a screening test in the general population or in patients with a normal thyroid on palpation and a low clinical risk of thyroid cancer (**Grade C; BEL 3**)
- US evaluation is recommended for (**Grade B; BEL 3**):
 - Patients at risk for thyroid malignancy
 - Patients with palpable thyroid nodules or MNGs
 - Patients with lymphadenopathy suggestive of a malignant lesion

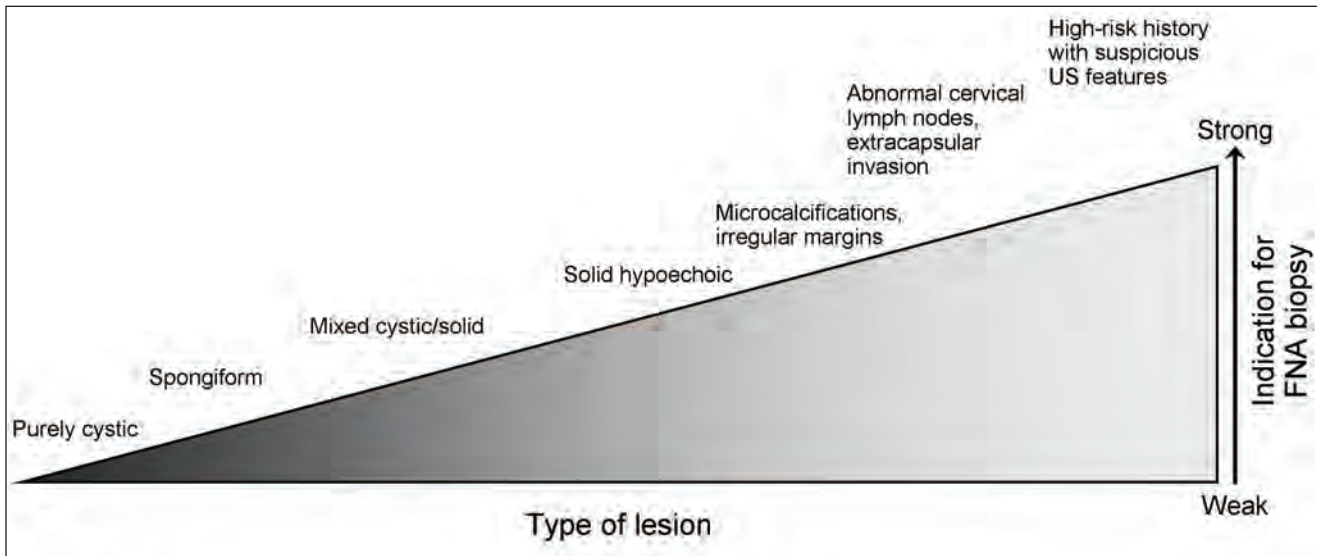


Fig. 2. Strength of indication for fine-needle aspiration (FNA) biopsy of thyroid nodules on the basis of ultrasonography (US) findings.

3.7.1.2. How to Describe US Findings

- Report should focus on risk stratification for malignancy (**Grade C; BEL 4**)
- Describe position, shape, size, margins, content, echogenic pattern, and vascular features of the nodule(s) (**Grade C; BEL 3**)
- For multiple nodules, detail the nodule(s) bearing the US characteristics associated with malignancy (hypoechoic pattern and/or irregular margins, a more-tall-than-wide shape, microcalcifications, or chaotic intranodular vascular spots) rather than describing the largest (“dominant”) nodule (**Grade C; BEL 3**)

3.7.2. Indications for FNA Biopsy

3.7.2.1. How to Select Nodule(s) for FNA Biopsy (**Grade B; BEL 3**):

- FNA biopsy is recommended for nodule(s):
 - Of diameter larger than 1.0 cm that is solid and hypoechoic on US
 - Of any size with US findings suggestive of extracapsular growth or metastatic cervical lymph nodes
 - Of any size with patient history of neck irradiation in childhood or adolescence; PTC, MTC, or MEN 2 in first-degree relatives; previous thyroid surgery for cancer; increased calcitonin levels in the absence of interfering factors
 - Of diameter smaller than 10 mm along with US findings associated with malignancy (see section 3.7.1.2.); the coexistence of 2 or more

suspicious US criteria greatly increases the risk of thyroid cancer

- Nodules that are hot on scintigraphy should be excluded from FNA biopsy (see difference in recommendations for children; section 8.4.)

3.7.2.2. FNA Biopsy of Multinodular Glands

- It is rarely necessary to biopsy more than 2 nodules when they are selected on the basis of previously described criteria (**Grade D**)
- If a radioisotope scan is available, do not biopsy hot areas (**Grade B; BEL 4**)
- In the presence of suspicious cervical lymphadenopathy, FNA biopsy of both the lymph node and suspicious nodule(s) is essential (**Grade B; BEL 4**)

3.7.2.3. FNA Biopsy of Complex (Solid-Cystic) Thyroid Nodule(s)

- Always sample the solid component of the lesion by UGFNA biopsy (**Grade B; BEL 4**)
- Submit both the FNA biopsy specimen and the drained fluid for cytologic examination (**Grade B; BEL 4**)

3.7.2.4. FNA Biopsy of Thyroid Incidentalomas

- Thyroid incidentalomas should be managed according to previously described criteria for nodule diagnosis (**Grade C; BEL 3**)
- Incidentalomas detected by CT or MRI should undergo US evaluation before consideration for UGFNA biopsy (**Grade C; BEL 3**)

- Incidentalomas detected by positron emission tomography with ^{18}F -fluorodeoxyglucose should undergo US evaluation plus UGFNA biopsy because of the high risk of malignancy (**Grade C; BEL 3**)

3.7.3. Other Diagnostic Imaging Techniques

- MRI and CT are not indicated for routine thyroid nodule evaluation (**Grade D**)
- MRI and CT are of value for assessment of size, airway compression, or substernal extension of a nodular goiter (**Grade C; BEL 3**)

3.7.4. Novel US Techniques

- Elastography and US contrast media currently are not used routinely in the evaluation of thyroid nodules (**Grade C; BEL 3**)

4. THYROID BIOPSY

4.1. Thyroid FNA Biopsy

Clinical management of thyroid nodules should be guided by the combination of US evaluation and FNA biopsy (Figs. 1 and 2) (8). FNA biopsy is currently the best triage test for the preoperative evaluation of thyroid nodules (56-58).

Because the most common cause of a false-negative cytologic diagnosis is sampling error (56), cytologic diagnosis is more reliable and the nondiagnostic rate is lower when FNA biopsy is performed with US guidance (UGFNA) (59-61). UGFNA biopsy is strongly recommended in palpable nodules, MNGs, and generally in obese patients and in men with well-developed cervical muscles. Hence, UGFNA biopsy is currently the single most important procedure for the management of thyroid nodules.

4.2. Cytologic Diagnosis

Thyroid smears or liquid-based cytology should be reviewed by a cytopathologist with a special interest in thyroid disease (62). The request form accompanying the cytologic specimen should include all the relevant clinical and US information (63,64). The cytologic report should be descriptive and, whenever possible, a diagnosis should be made (58,63).

The FNA biopsy sample must be adequate for an interpretation that yields a low false-negative rate (65). FNA biopsy results should be classified as diagnostic (satisfactory) or nondiagnostic (unsatisfactory). Even if the evaluation of adequacy is difficult to standardize (65,66), the specimen is labeled “diagnostic” if it contains a minimum of 6 groupings of well-preserved thyroid epithelial cells, consisting of at least 10 cells per group (67).

Cytologic diagnoses should be organized into 5 classes (nondiagnostic, benign, follicular lesion, suspicious, and malignant [62,63]):

Class 1. Specimens may be labeled as “nondiagnostic” because of an insufficient number of cells, which can be attributable to cystic fluid or bloody smears, or because of poor technique in preparing slides, leading to compromised preservation of the diagnostic material (66,67).

Class 2. A benign (or negative for malignancy) cytodiagnosis is the most common finding (66,67). Benign cytologic findings include colloid nodule, hyperplastic nodule, lymphocytic or granulomatous thyroiditis, and benign cyst.

Class 3. Follicular lesions include all follicular-patterned specimens for which a definite cytologic diagnosis of benign or malignant cannot be established on the basis of cytomorphology (62,63). These include adenomatoid hyperplasia, follicular adenoma and carcinoma, Hürthle cell neoplasms, and the follicular variant of PTC. Follicular lesions appear as hypercellular specimens with a monotony of cells, microfollicular arrangement, and decreased or absent colloid. Hürthle cell neoplasm is diagnosed in an aspirate that consists of almost entirely Hürthle cells, usually with absent or scanty colloid, and that lacks an associated lymphoid cell population, as found in Hashimoto thyroiditis. In centers with specific experience in thyroid cytology, follicular cytology may be further subdivided into “follicular lesion/atypia of undetermined significance” and “follicular neoplasm” (64). This distinction may separate 2 cytologic groups at different risk for thyroid malignancy (56,64), but with the same operative indications.

Class 4. Suspicious results include either samples with adequate cellularity characterized by cytologic features suggesting but not fulfilling the criteria for a definite diagnosis of malignancy or samples with poor cellularity and/or poor fixation and preservation but clear features indicating malignancy (63,64,66,68).

Class 5. Malignant (or positive) results include samples characterized by malignant cytologic features that are reliably identified by the cytopathologist (63,64,69). The most frequent malignant lesion encountered is PTC. Other malignant lesions include MTC, anaplastic carcinoma, lymphoma, miscellaneous thyroid tumors, and metastatic cancers (66,69).

4.3. FNA Biopsy Results

Most (60%-80%) results of FNA biopsy are classified as benign; for the rest, 10% to 20% are follicular lesion/neoplasm, 3.5% to 10% are malignant, 2.5% to 10% are suspicious, and 10% to 15% are nondiagnostic (56,63,65,69,70). The results of FNA biopsy are critical in deciding whether to manage the nodule medically or surgically. Selection of patients for surgical treatment on the basis of FNA biopsy

results has decreased the number of thyroid operations by about half and has increased the yield of cancer from 15% to 50% (57,71).

The sensitivity and specificity of FNA biopsy performed by experienced personnel are excellent, as shown in Table 1. The false-negative rate—a missed diagnosis of malignant disease—for palpation-guided FNA biopsy has been reported as 1% to 11% (mean, 5%) (56,70,72). The true incidence of malignancy in the benign class can only be determined with difficulty because a benign diagnosis is usually managed conservatively. However, with the use of UGFNA, the rate of false-negative FNA biopsy results, established on clinical grounds, is about 1% to 2% (61) and decreases further with repeated UGFNA biopsy (62). Methods for minimizing false-negative results are described in Box 3.

A false-positive diagnosis implies that no malignancy was detected in a surgically removed thyroid that had a class 5 FNA biopsy diagnosis. The reported incidence of false-positive results ranges from less than 1% to 7.7% (56,70). Most errors are interpretative, resulting from overlapping features, degenerative changes, an inadequate specimen, or cytopathologist inexperience (66,70). PTC is the most common false-positive diagnosis (66).

4.4. Large-Needle and Core-Needle Biopsy

Large-needle biopsy (LNB), performed without US guidance with a large-bore needle, is not recommended for thyroid nodules because of local pain and risk of cervical bleeding. It also does not add any further diagnostic information to FNA biopsy in nodules with follicular cytologic characteristics (73).

Core-needle biopsy (CNB), performed under US guidance with a 20- to 21-gauge cutting needle by experienced

operators, may offer additional information to FNA biopsy in selected cases of thyroid or neck masses with repeated inadequate FNA biopsy cytology (74). In patients with suspicious anaplastic tumor, thyroid lymphoma, pathologic lymph nodes, or other malignant neck disease, CNB frequently provides critical information for nodule management (64,75). However, CNB offers no additional diagnostic value in distinguishing a cellular hyperplastic nodule from a follicular adenoma or carcinoma (76). Hence, US-guided CNB should not be seen as an alternative to FNA biopsy, but as a complementary investigational tool (64,75).

4.5. Key Recommendations

4.5.1. Thyroid FNA Biopsy

- Clinical management of thyroid nodules should be guided by the combination of US evaluation and FNA biopsy (**Grade A; BEL 3**)
- Cytologic diagnosis is more reliable and the nondiagnostic rate is lower when FNA biopsy is performed with US guidance (**Grade B; BEL 3**)

4.5.2. Cytologic Reporting

- Thyroid smears or liquid-based cytology should be reviewed by a cytopathologist with a special interest in thyroid disease (**Grade C; BEL 3**)
- The request form accompanying the cytologic specimen should include all relevant clinical and US information (**Grade D**)
- The cytologic report should be descriptive, and, whenever possible, a diagnosis should be made (**Grade B; BEL 4**)

Table 1
Summary Characteristics for Thyroid Fine-Needle Aspiration: Results of Literature Survey

Feature, %	Mean	Range	Definition
Sensitivity	83	65-98	Likelihood that patient with disease has positive test results
Specificity	92	72-100	Likelihood that patient without disease has negative test results
Positive predictive value	75	50-96	Fraction of patients with positive test results who have disease
False-negative rate	5	1-11	Fine-needle aspiration negative; histology positive for cancer
False-positive rate	5	0-7	Fine-needle aspiration positive; histology negative for cancer

Adapted from Gharib H, Papini E, Valcavi R, et al; AACE/AME Task Force on Thyroid Nodules. American Association of Clinical Endocrinologists and Associazione Medici Endocrinologi medical guidelines for clinical practice for the diagnosis and management of thyroid nodules. *Endocr Pract.* 2006;12:63-102. Used with permission.

Box 3
Ways to Minimize False-Negative Results

Use ultrasound-guided fine-needle aspiration (UGFNA) biopsy
 Perform multiple punctures of the nodule so that several areas are sampled
 Consider repeated UGFNA biopsy for follow-up of benign nodules
 For multiple nodules, prioritize the nodule to biopsy according to ultrasonographic findings
 For cystic lesions, sample solid areas with UGFNA biopsy and submit cyst fluid for examination
 Obtain at least 6 properly prepared thin cell smears
 Use immediate wet fixation for Papanicolaou staining technique
 Review slides with an experienced cytopathologist

4.5.3. Cytologic Diagnosis

FNA biopsy results may be diagnostic (satisfactory) or nondiagnostic (unsatisfactory). Even if the evaluation of adequacy is difficult to standardize, the specimen is labeled “diagnostic” if it contains a minimum of 6 groupings of well-preserved thyroid epithelial cells, consisting of at least 10 cells per group (**Grade D; BEL 4**).

Cytologic diagnoses should be organized into 5 classes (**Grade B; BEL 3**):

- **Class 1. Nondiagnostic** (inadequate or insufficient): samples with processing errors or an insufficient number of follicular cells
- **Class 2. Benign** (or negative for malignancy): includes colloid or hyperplastic nodules, Hashimoto or granulomatous thyroiditis, and cysts
- **Class 3. Follicular lesions:** all follicular-patterned lesions, including follicular neoplasms, Hürthle cell lesions, and the follicular variant of PTC. In centers with specific experience in thyroid cytology, follicular cytologic findings may be further subdivided into “follicular lesion/atypia of undetermined significance” and “follicular neoplasm.” This distinction separates 2 cytologic groups at different risk for thyroid malignancy but with the same operative indications
- **Class 4. Suspicious:** samples that suggest a malignant lesion, but do not completely fulfill the criteria for a definite diagnosis
- **Class 5. Malignant** (or positive): samples characterized by malignant cytologic features that are reliably identified by the cytopathologist and are diagnostic of primary or metastatic tumors

4.5.4. Pitfalls in FNA Biopsy

- False-negative results are usually due to inadequate sampling or inappropriate target selection (**Grade D**)
- False-positive results are usually due to specimens with suspicious findings (**Grade D**)

- Gray zones in cytologic reports are follicular lesions and cytologic findings suggestive of but not diagnostic for PTC (**Grade D**)
- In follicular lesions, consider performing thyroid scintigraphy to exclude a hot nodule at very low risk for malignancy (**Grade B; BEL 3**)

4.5.5. Ways to Minimize False-Negative Results

- Use UGFNA biopsy (**Grade C; BEL 3**)
- Aspirate multiple nodule sites (**Grade C; BEL 4**)
- For multiple nodules, prioritize the nodules to biopsy according to US findings (**Grade B; BEL 3**)
- For cystic lesions, sample solid areas with UGFNA biopsy and submit cyst fluid for examination (**Grade C; BEL 4**)
- Review slides with an experienced cytopathologist (**Grade D**)
- Follow-up cytologically benign nodule(s) (**Grade D**)
- Consider performing a repeated UGFNA biopsy for follow-up of benign nodules (**Grade C; BEL 3**)

4.5.6. Core-Needle Biopsy

- CNB performed under US guidance may offer additional information in selected cases with thyroid or neck masses and inadequate FNA biopsy cytologic results (**Grade C; BEL 3**)

5. LABORATORY EVALUATION

5.1. Assessment of Thyroid Function

The high sensitivity of the TSH assay for detecting even subtle thyroid dysfunction makes it the most useful laboratory test in the initial evaluation of thyroid nodules (77). Measuring serum levels of free thyroid hormones and TPOAb or anti-TSH-receptor antibody (TRAb) should be the second diagnostic step, which is necessary for confirmation and the subsequent definition of thyroid dysfunction if the TSH concentration is outside the reference range (78).

5.2. TSH Assay

Third-generation TSH chemiluminometric assays, with detection limits of about 0.01 microunits/mL, should be used in current clinical practice. They can detect decreased TSH levels even in mild cases of hyperthyroidism and allow a reliable diagnosis of mild (subclinical) thyroid hyperfunction (77,78).

5.3. Serum Free Thyroxine and Free Triiodothyronine

If the serum TSH level is within the reference range, the measurement of free thyroid hormones adds no further relevant information. If TSH levels are low, however, measurement of free thyroxine and free triiodothyronine levels is necessary to confirm the presence of hyperthyroidism or consider central hypothyroidism, in which TSH can be normal or low and free thyroxine levels may be low (79).

To limit unnecessary laboratory testing, the following strategy should be followed for most patients with thyroid nodules (78,79):

- Serum TSH level within normal limits: no further testing (unless suspicion of central hypothyroidism)
- Increased serum TSH: test free thyroxine and TPOAb to evaluate for hypothyroidism
- Decreased serum TSH: test free thyroxine and triiodothyronine to evaluate for hyperthyroidism

5.4. Antibody Assays

TPOAb should be measured in patients with high levels of serum TSH (79,80). High serum TPOAb values and a firm, diffusely enlarged, or small thyroid are very suggestive of autoimmune or Hashimoto thyroiditis (11,80,81). Occasionally, a nodular goiter may represent Hashimoto thyroiditis (80).

Antithyroglobulin antibody testing should be reserved for patients with US and clinical findings suggestive of chronic lymphocytic thyroiditis in conjunction with normal serum TPOAb levels (79).

TRAb determination should be performed in patients with hyperthyroidism for more complete etiologic clarification (82), because 17% of patients in iodine-deficient areas with scintigraphic criteria for toxic MNG are positive for TRAb (83).

5.5. Thyroglobulin Assay

Assessment of serum thyroglobulin is not recommended in the diagnosis of thyroid nodules (84). In patients undergoing surgery for malignancy, testing of serum thyroglobulin may be considered so as not to overlook a false-negative serum thyroglobulin value due to decreased thyroglobulin immunoreactivity or heterophilic antibodies (85).

5.6. Calcitonin Assay

Calcitonin is a serum marker for MTC and correlates with tumor burden (86). Calcitonin testing is imperative in patients with a history or a clinical suspicion of familial MTC or MEN 2 (87). Calcitonin measurement is recommended if FNA biopsy results are suggestive of MTC and in patients with nodular goiters undergoing thyroid surgery to avoid the risk of inadequate surgical treatment (88,89). Routine testing of serum calcitonin for MTC in all patients with unselected thyroid nodules is still debated (90). Studies of nodular thyroid disease have reported a prevalence of MTC ranging from 0.4% to 1.4% of all patients (80,88,89,91,92). Calcitonin levels can be increased in patients with pulmonary or pancreatic endocrine tumors, kidney failure, autoimmune thyroid disease, or hypergastrinemia (resulting from proton-pump inhibitor therapy); other factors that increase calcitonin are alcohol consumption, smoking, sepsis, and heterophilic anticalcitonin antibodies (93-95). In addition, sex, age, weight, increased calcium levels, and the assay itself also affect the calcitonin level (93-95). Cutoff values, such as 10 or 20 pg/mL, have been effectively used for the screening of unselected nodules (92,96). The false-positive rate decreases with increasing cutoff levels. Therefore, a single nonstimulated calcitonin measurement can be used in the routine workup of thyroid nodules. If the calcitonin value is increased, the test should be repeated and, if confirmed in the absence of the above modifiers, pentagastrin-stimulation testing will increase the diagnostic accuracy (92,96). The availability of pentagastrin is limited outside Europe; in the United States, calcitonin stimulation may be performed with calcium. The diagnostic value of calcium-stimulation test results has not been completely assessed (96), but a cutoff for the response in healthy subjects is under investigation (97).

Screening of at-risk family members should be done by testing for germline mutations in the *RET* proto-oncogene (87,98). Screening for *RET* proto-oncogene germline mutations in apparently sporadic MTC may detect MEN 2 in about 5% of cases (99).

5.7. Key Recommendations

5.7.1. Laboratory Evaluation in Patients With Thyroid Nodules

- Always measure serum TSH (**Grade A; BEL 3**)
- If TSH level is decreased, measure free thyroxine and total or free triiodothyronine; if TSH level is increased, measure free thyroxine and TPOAb (**Grade B; BEL 3**)
- Testing for antithyroglobulin antibodies should be restricted to patients with US and clinical findings suggestive of chronic lymphocytic thyroiditis

when serum levels of TPOAb are normal (**Grade C; BEL 3**)

- Assessment of serum thyroglobulin is not recommended in the diagnosis of thyroid nodules. In patients undergoing surgery for malignancy, serum thyroglobulin measurement may be useful to detect potential false-negative results (**Grade C; BEL 3**)
- TRAb measurement should be performed in patients with TSH levels below the reference range (**Grade D**)

5.7.2. Calcitonin

- Measurement of basal serum calcitonin level may be a useful test in the initial evaluation of thyroid nodules (**Grade B; BEL 3**)
- Measurement of nonstimulated serum calcitonin level may be considered before thyroid surgery for nodular goiter (**Grade B; BEL 3**)
- Measurement is mandatory in patients with a family history or clinical suspicion of MTC or MEN 2 (**Grade A; BEL 2**)
- If calcitonin level is increased, the test should be repeated and, if confirmed in the absence of modifiers, a pentagastrin- or calcium-stimulation test will increase the diagnostic accuracy (**Grade B; BEL 3**)

5.7.3. Other Tests

- Measure serum calcium, parathyroid hormone, or both if a nodular lesion is suggestive of intrathyroidal parathyroid adenoma on US examination (**Grade D**)

6. RADIONUCLIDE SCANNING

6.1. Thyroid Scintigraphy

Thyroid scintigraphy is the only technique that allows for assessment of thyroid regional function and detection of areas of AFTN (100).

6.2. Diagnostic Accuracy

On the basis of the pattern of radionuclide uptake, nodules may be classified as hyperfunctioning (“hot”), hypofunctioning (“cold”), or indeterminate (100). Hot nodules almost never represent clinically significant malignant lesions, whereas cold or indeterminate nodules have a reported malignancy risk of 3% to 15% (42,101-103).

Because most thyroid lesions are cold or indeterminate and only a small minority of them are malignant (104,105), the predictive value of hypofunctioning or indeterminate nodules for the presence of malignant involvement is low. The diagnostic specificity is further decreased in small lesions (<1 cm) that are below the resolution threshold of scintigraphy (100,106,107).

The role of scintigraphy in the diagnostic workup of thyroid nodules is limited in countries with iodine-rich diets, in which serum TSH measurement and thyroid US can correctly diagnose autonomous nodules in most patients (106,107), and FNA biopsy facilitates accurate diagnosis of a malignant lesion (71). Moreover, because the resolution of US is considerably greater than that of scintigraphy, radionuclide scanning has little place in the topographic assessment of nodular goiter and no place in the measurement of thyroid nodules.

However, in geographic regions with iodine deficiency, thyroid scintigraphy is used as part of the evaluation of patients with MNG (100,108) because it provides useful information on the functional characterization of thyroid nodules. It allows early diagnosis of thyroid autonomy and prioritization of cold and indeterminate nodules in MNGs for FNA biopsy (100). In patients in these regions, the serum TSH may remain unsuppressed even if autonomy is present because of the low proliferation rate of thyroid epithelial cells and the low synthesis rate of thyroid hormones by iodine-depleted thyroid glands (109). Moreover, in the early phases of autonomy, the bulk of autonomous tissue may be insufficient to suppress the TSH level (100,106,109,110). The early recognition of autonomous nodules, before they induce the suppression of TSH, enables early treatment to avoid thyroid growth and progression toward manifest hyperthyroidism (111). Furthermore, in iodine-deficient euthyroid goiters, microscopic areas of hot thyroid tissue contain constitutively activating TSH receptor mutations, which increase the risk of iodine-induced hyperthyroidism (111).

Quantitative pertechnetate scintigraphy (calculation of technetium thyroid uptake under suppression) is a sensitive and specific technique for the diagnosis and quantitation of thyroid autonomy and is a reliable predictor of hyperthyroidism in the setting of euthyroid autonomy (100).

Thyroid scintigraphy can be performed with ^{123}I or $^{99\text{m}}\text{TcO}_4^-$ (sodium pertechnetate). Each of these imaging agents has advantages and disadvantages.

$^{99\text{m}}\text{TcO}_4^-$

- Advantages: less expensive; more readily available; more rapid examination
- Disadvantages: technetium is trapped but not organified (risk of false-positive images); activity in esophagus or vascular structures can be misleading; poor image quality when uptake is low

^{123}I

- Advantages: better visualization of retrosternal thyroid tissue; better images when thyroid uptake is low; real iodine clearance of the thyroid may be measured instead of Tc uptake as a surrogate parameter
- Disadvantages: higher cost; less comfortable for the patient (delayed imaging at 24 hours is often

used); less readily available; imaging times usually longer

6.3. Indications for Thyroid Scintigraphy

Thyroid scintigraphy is indicated in the following settings (108-111):

- With a single thyroid nodule and suppressed TSH level; FNA biopsy is not necessary for hot nodules
- For MNGs, even without suppressed TSH, to identify cold or indeterminate areas for FNA biopsy and hot areas that do not need cytologic evaluation
- For large MNGs, especially with substernal extension
- In the diagnosis of ectopic thyroid tissue
- In subclinical hyperthyroidism to identify occult hyperfunctioning tissue
- In follicular lesions to identify a functioning cellular adenoma that may be benign; however, most such nodules are cold on scintigraphy
- To determine eligibility for radioiodine therapy
- To distinguish low-uptake from high-uptake thyrotoxicosis

6.4. Key Recommendations

6.4.1. When to Perform Thyroid Scintigraphy

- Perform scintigraphy for a thyroid nodule or MNG if the TSH level is below the lower limit of the reference range or if ectopic thyroid tissue or a retrosternal goiter is suspected (**Grade B; BEL 3**)
- In iodine-deficient regions, consider performing scintigraphy to exclude autonomy for a thyroid nodule or MNG even if TSH is normal (**Grade C; BEL 3**)

6.4.2. How to Perform Thyroid Scintigraphy

- Either ^{123}I or $^{99\text{m}}\text{TcO}_4^-$ (sodium pertechnetate) can be used for thyroid scintigraphy (**Grade B; BEL 3**)
- ^{131}I thyroid uptake is not recommended for routine diagnostic use unless low-uptake thyrotoxicosis is suspected (**Grade A; BEL 3**)

7. MANAGEMENT AND THERAPY

Clinical management of thyroid nodules should be guided by the results of US evaluation and FNA biopsy (8,112) (Figs. 1 and 2).

7.1. Nondiagnostic Nodules by FNA Biopsy (Class 1)

Nondiagnostic FNA biopsy specimens usually result from cystic nodules that yield few or no follicular cells; benign or malignant sclerotic lesions; nodules with a thick or calcified capsule; abscesses; and hypervascular or necrotic

lesions (113-115). Additional causes of nondiagnostic results may be sampling errors or faulty biopsy techniques. Reaspiration yields satisfactory results in 50% to 62% of cases (66,69). The timing of repeated needle aspiration has not been established, but a waiting period of at least 3 months should elapse before reaspiration, unless the clinical suspicion for malignancy is high (64,66).

Despite good initial technique and repeated biopsy, 5% to 30% of nodules remain nondiagnostic because of factors inherent to the lesion (66). In these cases, the use of US guidance (59) and a stylet (116) or thin-core needle may further decrease the risk of a nondiagnostic sample (75).

In nondiagnostic specimens, the reported malignancy rate is from 2% to 12% (66). Nondiagnostic aspirates composed of pure colloid and obtained from a nodule that is completely cystic on US require clinical and US follow-up. Aspirates of complex lesions containing blood and histiocytes need careful correlation with family history and with clinical and US findings, and, in the case of repeated nondiagnostic UGFNA, should be considered for surgical resection (57,66). Most nondiagnostic solid nodules should be surgically excised, but some, on the basis of clearly favorable clinical and US findings, may be followed up with close clinical and US surveillance (8,112).

7.2. Benign Nodules by FNA Biopsy (Class 2)

7.2.1. Clinical Follow-Up or Levothyroxine Suppressive Therapy

Most thyroid nodules with benign cytologic results and no clinical and US risk factors should be followed up clinically (2,3,8). The timing of clinical and US follow-up and the role of routine rebiopsy of benign nodules are still unclear (117,118). In most cases, clinical and US examination and TSH measurement are appropriate in 6 to 18 months. A routine repeated FNA biopsy may be considered in patients with initially benign cytologic results because of the low, but not negligible, possibility of false-negative results (119). Reaspiration under US guidance is recommended if a nodule significantly enlarges, if a cyst reappears, or in case of suspicious clinical or US changes (8,112).

A clinically significant (>50%) decrease in nodule volume is obtained with levothyroxine therapy in a minority of patients with palpable thyroid nodules (120). Reduction of nodule volume with levothyroxine seems to be more effective in small thyroid nodules with colloid features at FNA biopsy and in geographic regions with iodine deficiency (121). Long-term TSH suppression may prevent an increase in size of a thyroid nodule and of the thyroid gland itself (122,123), but nodule regrowth occurs after cessation of therapy; thus, commitment to long-term therapy seems inevitable. Levothyroxine suppressive therapy is not useful for prevention of goiter recurrence after lobectomy

in patients with normal TSH levels (124,125). Moreover, sustained subclinical hyperthyroidism is associated with a decrease in bone density in postmenopausal women (126,127). In elderly patients with suppressed levels of serum TSH, a 3-fold increase in atrial fibrillation has been reported (128,129).

Routine levothyroxine treatment in patients with nodular thyroid disease is not recommended. Levothyroxine therapy or iodine supplementation (130) may be considered in young patients who live in iodine-deficient geographic areas and have small thyroid nodules and in those who have nodular goiters and no evidence of functional autonomy (122,123). The use of levothyroxine should be avoided in patients with large thyroid nodules or longstanding goiters; in patients with low-normal TSH levels; in postmenopausal women; in men older than 60 years; and in patients with osteoporosis, cardiovascular disease, or systemic illnesses (127,129).

7.2.2. Surgical Indications

The following situations are indications for surgical treatment in a patient with a benign thyroid nodule: neck pressure, dysphagia, a choking sensation, shortness of breath (especially when supine), dyspnea on exertion, hoarseness, or pain (2). It is important to verify that the symptoms are associated with the nodule or goiter and not with other disease processes, such as pulmonary or cardiac disease, esophageal disorders, or other head, neck, or lung tumors (8). If a thyroid nodule shows a significant increase in volume or a change in its US features, despite benign FNA biopsy results, surgical resection should be considered (112).

A symptomatic uninodular goiter or MNG, whether euthyroid or hyperthyroid, may be treated surgically or with radioiodine. The preferred extent of resection is lobectomy plus isthmectomy for benign uninodular goiter and (near) total thyroidectomy for MNG (62,125).

7.2.3. US-Guided Minimally Invasive Procedures

Minimally invasive thyroid surgery may be performed with minimum surgical risk in patients with small nodules (131,132). In recent years, percutaneous, image-guided, minimally invasive therapeutic procedures have been proposed for the nonsurgical management of thyroid nodules in selected cases (133,134).

7.2.3.1. Percutaneous Ethanol Injection

Percutaneous fluid drainage may cure thyroid cysts; however, recurrences are common and surgery is often the final treatment of large relapsing lesions (135). Prospective randomized trials and long-term studies have shown that percutaneous ethanol injection (PEI) is significantly superior to aspiration alone for inducing volume reduction in cysts and complex nodules with a dominant fluid component (136-139). Volume reduction is followed by

disappearance of local pressure symptoms (140). The recurrence rate of cystic lesions successfully treated with PEI is low, but in large or multilocular thyroid cysts several injections may be necessary (136).

For hyperfunctioning thyroid nodules, short-term volume reduction is satisfactory (141,142), but 5 years after PEI, serum TSH is suppressed in most cases (136). Hence, PEI is not indicated for hyperfunctioning nodules or nodular goiters because of a high recurrence rate and the availability of effective alternative treatment options.

Clinically significant decreases in nodule size after PEI are reported in solid thyroid nodules that are cold on scintigraphy (143,144). The response, however, is less impressive than in cysts, more treatments are needed, and adverse effects are more frequent (136).

7.2.3.2. Thermal Ablation

Thermal ablation with radiofrequency has been proposed for the debulking of large benign thyroid nodules (145,146). Radiofrequency ablation (RFA) is based on the percutaneous insertion of large needle electrodes (14- to 18-gauge) or hook needles and is usually performed under conscious sedation. Because of some disadvantages and the absence of prospective randomized trials, RFA is currently not recommended in the routine management of benign thyroid nodules.

US-guided thermal ablation with laser (percutaneous laser ablation [PLA]) allows the use of small (21-gauge) and multiple (up to 4) needles with a minimally invasive procedure (134). In most patients with thyroid nodules, 1 to 3 sessions of PLA or a single treatment with multiple fibers induces a clinically significant decrease in nodule volume and the amelioration of local symptoms (147). PLA is performed with local anesthesia. Two randomized trials have confirmed its safety and clinical efficacy (148,149).

Because of the novelty of the PLA technique, long-term follow-up studies are lacking (150). Therefore, PLA should be restricted to patients with pressure symptoms or cosmetic concerns who decline surgery or are at surgical risk. Because of potential complications, thermal ablation procedures should be performed only by experienced operators.

7.2.4. Radioiodine Treatment for Hyperfunctioning Nodules

Radioiodine is indicated for the treatment of hyperthyroidism attributable to a hyperfunctioning nodule or a toxic MNG (151). The aims of radioiodine treatment are the ablation of the autonomously functioning areas, the achievement of euthyroidism, and the reduction of goiter size (80,151-153). AFTNs are usually more radioresistant than are toxic diffuse goiters, and higher radiation doses may be needed for successful treatment, especially in countries with iodization programs leading to decreased uptake of radioactive iodine (80,154).

Radioiodine therapy normalizes thyroid function in 85% to 100% of patients with hyperfunctioning thyroid nodules or toxic MNGs (154). After treatment, the thyroid volume generally decreases substantially (median decrease, 35% at 3 months and 45% at 24 months) (152). Radioiodine treatment is generally thought to be effective and safe. Although some investigators have indicated that radioiodine treatment may be associated with increased cardiovascular and cancer mortality (155), other large-scale epidemiologic studies have demonstrated discordant results (156).

After ablation of the autonomous tissue, most patients become euthyroid because of residual normal thyroid tissue, which is no longer suppressed. Nevertheless, depending on the dose of radioiodine used, follow-up of thyroid function, and the possible presence of autoimmune thyroiditis, postradioiodine hypothyroidism may develop in up to 60% after 20 years (157,158). In up to 5% of patients, immunogenic hyperthyroidism may result from radioiodine treatment of toxic or nontoxic nodular goiter (158,159) because of induction of TRAbs (160). This typically occurs 3 to 6 months after radioiodine treatment and could be due to initially undetectable TRAbs in Graves disease (161).

Ingestion of drugs with a high iodine content (such as amiodarone or a saturated solution of potassium iodide) should be avoided before administration of radioiodine, so as not to impair radioiodine uptake by the thyroid. If possible, antithyroid drugs (especially propylthiouracil) (162) should be withdrawn at least 1 week before treatment to prevent radioiodine uptake by normal thyroid tissue and to increase the uptake in the hot thyroid tissue. Use of antithyroid drugs during the first week after radioiodine therapy also decreases the efficacy of the radioiodine treatment. However, it also decreases biochemical and clinical hyperthyroidism and complications such as atrial fibrillation (163).

Radioiodine treatment is best suited for small- to medium-sized benign goiters, for patients previously treated surgically, for those with serious comorbid conditions, or for those who decline surgery (164). However, radioiodine is not suited for large nodules that require high doses of radioiodine and may be unresponsive to treatment, or if an immediate resolution of hyperthyroidism is desired (164). The only absolute contraindications to radioiodine treatment are breastfeeding and pregnancy, which should be excluded by a pregnancy test (80,151,153). There is no consensus on a lowest age limit.

7.2.5. Radioiodine Treatment for Nodular Goiter

The use of radioiodine for the treatment of nontoxic nodular goiter has been reported in numerous studies from geographic areas with relatively low dietary intake of iodine (80,165-169). In these reports, patients with MNG had increased or high-normal 24-hour radioiodine uptake

compared with that in similar patients with MNG in the United States. There are no studies comparing radioiodine therapy with and without dietary iodine restriction.

In general, a 40% to 50% decrease in thyroid size after 1 year (80,165,166,170) and a 50% to 60% decrease after 3 to 5 years can be achieved with radioiodine therapy (79,164), half of which is seen within 3 months (164). The degree to which goiter volume decreases varies greatly, and 20% do not seem to respond at all. In a randomized study (170), levothyroxine had no effect, whereas radioiodine decreased goiter size by 50% after 1 to 2 years. In very large goiters (>100 mL), goiter volume decreased by only 30% to 40% after 1 year, and the amount of decrease correlated inversely with initial goiter size (167,171). Theoretically, the effect of radioiodine depends on the retained dose in the thyroid. Generally, radioiodine activities have been adjusted according to radioiodine uptake, aiming at an absorbed dose of 100 Gy (156,171), but it has been questioned whether this adjustment is worthwhile (172). Because of regulations regarding allowed radiation doses, which vary considerably between countries, many physicians use fixed doses limited to the maximum outpatient activity to avoid hospitalizing the patients. Use of radioiodine usually improves symptoms and respiratory function (80,171).

Early adverse effects of radioiodine are generally mild and transient (164). They include radiation thyroiditis in approximately 3%, transient thyrotoxicosis in 5%, and occasionally an up to 25% increase in thyroid size. Late adverse effects are currently limited to hypothyroidism in 22% to 58% within 5 to 8 years after therapy. Although the risk of malignancy generally is not thought to be increased, no large-scale studies have been conducted in patients with nontoxic goiter, as opposed to toxic goiter. There are no studies comparing radioiodine therapy with surgery and no quality-of-life data using a validated thyroid-specific quality-of-life questionnaire.

7.2.6. Recombinant Human TSH–Stimulated Radioiodine for Nontoxic Goiter

Currently, the use of recombinant human TSH (rhTSH) for nontoxic goiter is off label; however, studies are underway to obtain United States Food and Drug Administration and European Medicines Agency approval. The main reason for using rhTSH is based on a desire to increase radioiodine uptake in the vast number of patients with low uptake and to decrease extrathyroidal radioiodine uptake, thereby decreasing the risk of malignancy and facilitating the decrease in goiter size (169,173).

The optimal dose of rhTSH and its timing in relation to subsequent radioactive iodine therapy are not clear. Recent data, however, suggest that radioiodine uptake is doubled with use of rhTSH doses as small as 0.03 to 0.1 mg without an evident dose-response relationship (169). Knowing that

it takes time to activate the thyroid sodium-iodine symporter, an interval of 24 to 48 hours between rhTSH stimulation and radioiodine administration seems optimal (169).

When used in combination with radioiodine therapy, rhTSH decreases goiter volume 35% to 56% more than nonstimulated radioiodine therapy (171,174,175). It also improves respiratory function (171). However, it is unclear whether its use increases patient satisfaction (174). The goiter-decreasing effect increases with increasing thyroid size, in contrast to the effect without rhTSH prestimulation. An alternative is to reduce radioiodine activity corresponding to the increase in radioiodine uptake obtained with rhTSH stimulation, while obtaining the same decrease in goiter size (176). This decreases radioiodine activity and, thereby, the theoretical risk of extrathyroidal malignancy. The induction of transient dose-dependent hyperthyroidism is the main adverse effect, starting 4 to 8 hours after rhTSH injection and peaking after 24 to 48 hours, with normalization within 3 weeks. With rhTSH doses of 0.1 mg or less, thyroid hormone levels are maintained within the reference range for most patients (176), with no alterations in structural or functional parameters of the heart (177). Acute (within 24-48 h) dose-related swelling of the normal thyroid has been demonstrated, with an increase in mean thyroid volume of 35% for 0.9 mg rhTSH, 24% for 0.3 mg rhTSH, and 10% for 0.1 mg rhTSH (173,174). Therefore, the optimal rhTSH dose seems to be 0.1 mg or less (178,179).

The main long-term complication of rhTSH use is an increase in the rate of hypothyroidism: 3 randomized studies (171,174,175) showed up to 5-fold increases in the rate of hypothyroidism in the rhTSH groups (21%, 61%, and 65%) compared with the rates in corresponding control groups (7%, 11%, and 21%, respectively). As seen with conventional radioiodine therapy, the incidence of hypothyroidism is positively related to goiter volume reduction. It is unclear whether rhTSH-stimulated radioiodine therapy increases the risk of thyroidal and extrathyroidal malignancy.

7.3. Follicular Lesions by FNA Biopsy (Class 3)

The follicular category is used when cytologic features indicate a follicular-patterned lesion for which a definite cytologic diagnosis of malignancy cannot be made. Currently, no clear-cut morphologic criteria are available to distinguish benign from malignant lesions (57,64,66). Repeated biopsy of nodules classified as follicular neoplasm is not recommended because it creates confusion and does not provide additional useful information for management (8). However, FNA biopsy may be repeated in cases diagnosed as “atypical cells” to exclude a follicular neoplasm (64). At surgical intervention, about 20% of such specimens are determined to be malignant lesions (57,64,180). CNB is not recommended in the management

of follicular nodules because it does not provide additional information (64).

Clinical criteria (Box 2) may be associated with increased risk of malignancy (181), but their predictive value is low (180). US features and US elastography may provide adjunctive information for assessing the risk of malignancy in cases with follicular cytologic characteristics. However, the specificity and reproducibility of these tools are limited (52,112).

Molecular and immunohistochemical markers may improve the accuracy of cytologic diagnosis, but they do not have consistent predictive value for malignancy and their use is still expensive and restricted to specialized centers (182,183). On the basis of current limited evidence, routine use of molecular and immunohistochemical markers in clinical practice is not recommended and should be reserved for selected cases (14,63).

Surgical excision of the lesion and histologic examination should be performed in most cases. Patients with follicular thyroid lesions can be treated with thyroid lobectomy and isthmectomy or total thyroidectomy, depending on the clinical situation and patient preference. Frozen section is usually not recommended (63,64) but may be useful in nodules with an ill-defined capsule, or in case of nontotal thyroidectomy to decrease the risk of completion thyroidectomy in the scenario of cancer diagnosis.

In cases with favorable clinical, cytologic, and US features, a multidisciplinary team may consider clinical follow-up without immediate diagnostic surgery (62,63,184).

7.4. Suspicious Nodules by FNA Biopsy (Class 4)

This category includes samples characterized by cytologic features that suggest malignancy, but do not fulfill the criteria for a definite diagnosis; it also includes samples with inadequate cellularity but with cellular features strongly suggestive of malignancy (62,63). The rate of histologically confirmed malignancy in these cases is about 60% (58). Most of these cases are determined to be PTC on definitive histologic analysis (63,68).

Surgery with intraoperative histologic examination is recommended (63). Frozen section may be performed to help guide surgical decision making (63,185). FNA biopsy may be repeated according to the clinician’s or cytopathologist’s opinion if more material is needed for ancillary studies (eg, immunocytochemistry or flow cytometry) (63,64).

7.5. Malignant Nodules by FNA Biopsy (Class 5)

Whenever possible, the type of carcinoma should be stated in the cytologic report (63,64). If cytologic results are compatible with a differentiated thyroid carcinoma, surgical intervention is necessary (62,186-188). If cancer is due to metastatic disease, efforts should be directed toward finding the primary lesion, which often precludes a

thyroid surgical procedure. For anaplastic carcinoma and lymphoma, further diagnostic workup is recommended before surgery (63).

Thyroid US and cytologic results should be reviewed with the patient and family, and treatment options should be discussed (62). Surgical excision should be recommended and its potential complications discussed. Consultation with a surgeon experienced in endocrine surgical procedures should be obtained as soon as possible (62). The surgical approach should be planned according to the clinical setting and imaging findings (188,189).

Preoperatively, in addition to evaluation by an anesthesiologist, patients with documented thyroid cancer should have US examination of the neck, UGFNA biopsy of any concomitant suspicious nodule or lymph node, and vocal cord assessment (188). In case of suspicious US features, the metastatic nature of a malignant cervical mass should be confirmed with measurement of thyroglobulin or calcitonin in the washout of the needle used for UGFNA biopsy (43,188,190).

MRI and CT may be performed in selected cases, if needed for the assessment of nodal or airway involvement, substernal extension, or pulmonary metastatic disease (55,191,192).

Treatment and management of thyroid cancer are not covered by this guideline.

7.6. Key Recommendations

7.6.1. Nodules Nondiagnostic by FNA Biopsy (Class 1)

- If initial FNA biopsy is nondiagnostic, it should be repeated with US guidance (**Grade B; BEL 3**)
- Most persistently nondiagnostic solid nodules should be surgically excised (**Grade C; BEL 4**)
- CNB may offer additional information in thyroid lesions with inadequate cytologic results of FNA biopsy (**Grade C; BEL 3**)

7.6.2. Nodules Benign by FNA Biopsy (Class 2)

7.6.2.1. Follow-Up

- Cytologically benign nodules should be followed up (**Grade C; BEL 3**)
- Perform repeated clinical and US examination and TSH measurement in 6 to 18 months (**Grade D**)
- Perform repeated UGFNA biopsy in cases of appearance of clinically or US suspicious features (**Grade B; BEL 3**)
- Perform repeated UGFNA biopsy in cases of a greater than 50% increase in nodule volume (**Grade B; BEL 3**)
- Consider routine repeated UGFNA biopsy in 6 to 18 months, even in patients with initially benign cytologic results (**Grade D**)

7.6.2.2. Levothyroxine Therapy for Benign Nodules

- Routine levothyroxine therapy is not recommended (**Grade B; BEL 1**)
- Levothyroxine therapy or iodine supplementation may be considered in young patients with small nodular goiter and no evidence of functional autonomy (**Grade B; BEL 1**)
- Levothyroxine therapy is not recommended for preventing recurrence after lobectomy if TSH remains normal (**Grade B; BEL 1**)

7.6.2.3. Surgical Indications for Benign Nodules

- Presence of local pressure symptoms clearly associated with the nodule(s), previous external irradiation, progressive nodule growth, suspicious US features, or cosmetic issues (**Grade D**)
- The preferred extent of resection for benign uninodular goiter is lobectomy plus isthmectomy and for MNG is (near) total thyroidectomy (**Grade D**)

7.6.2.4. US-Guided PEI

- PEI is effective in the treatment of benign thyroid cysts and complex nodules with a large fluid component (**Grade B; BEL 1**)
- PEI should not be performed in solitary solid nodules, whether hyperfunctioning or not, or in MNGs (**Grade C; BEL 3**)

7.6.2.5. Image-Guided Thermal Ablation

- Laser ablation may be considered for the treatment of thyroid nodules causing pressure symptoms or cosmetic issues in patients who decline surgery or are at surgical risk. Its use should be restricted to specialized centers (**Grade C; BEL 2**)
- RFA is not recommended in the routine management of thyroid nodules (**Grade C; BEL 3**)

7.6.2.6. Radioiodine Therapy for Benign Nodular Goiter

7.6.2.6.1. Considerations

- Indications are hyperfunctioning and/or symptomatic goiter, previous thyroid surgery, or surgical risk (**Grade B; BEL 2**)
- Before treatment, UGFNA biopsy should be performed per the recommendations given for non-toxic MNG (**Grade B; BEL 3**)
- Avoid use of iodine contrast agents or iodinated drugs before administration of radioiodine; withdraw antithyroid drugs at least 1 week before treatment and consider resumption 1 week after radioiodine therapy (**Grade B; BEL 2**)

7.6.2.6.2. Contraindications

- Radioiodine is contraindicated in pregnant or breastfeeding women (**Grade A; BEL 2**)

- Always perform a pregnancy test before administration of radioiodine in women of childbearing age (**Grade A; BEL 2**)

7.6.2.6.3. Follow-Up After Radioiodine Therapy

- Regular thyroid function monitoring is mandatory (**Grade B; BEL 3**)
- Consider repeating treatment in cases of persistent or recurrent hyperthyroidism or inadequate size reduction (**Grade C; BEL 3**)

7.6.3. Follicular Lesions (Class 3)

7.6.3.1. Management

- Repeated FNA biopsy of follicular lesions is not recommended because it does not provide additional information (**Grade C; BEL 3**)
- CNB is not recommended in the management of follicular lesions because it does not add additional information to FNA biopsy (**Grade D; BEL 4**)
- Molecular and histochemical markers are currently not recommended for routine use; their use may be considered in selected cases (**Grade D; BEL 3**)

7.6.3.2. Treatment

- Surgical excision is recommended for most follicular thyroid lesions (**Grade B; BEL 3**)
- Intraoperative frozen section is not recommended as a routine procedure (**Grade D**)
- Consider clinical follow-up in the minority of cases with favorable clinical, US, cytologic, and immunocytochemical features (**Grade D**)

7.6.4. Management of FNA Biopsy–Suspicious Nodules (Class 4)

- Surgery is recommended (**Grade B; BEL 3**)
- Intraoperative frozen section is useful (**Grade D**)

7.6.5. Nodules Malignant by FNA Biopsy (Class 5)

7.6.5.1. Management

- For a thyroid nodule with FNA biopsy results positive for differentiated thyroid carcinoma, surgical treatment is recommended (**Grade A; BEL 3**)
- For anaplastic carcinoma, metastatic lesions, and lymphoma, further diagnostic workup is recommended before surgery (**Grade B; BEL 3**)

7.6.5.2. Preoperative Evaluation

- Review US and cytologic results with the patient; discuss treatment options and obtain consultation with a surgeon experienced in endocrine surgery (**Grade D**)

- US examination of the neck, UGFNA biopsy of any concomitant suspicious nodule or lymph node, and vocal cord assessment should be performed before surgery (**Grade B; BEL 3**)
- In case of suspicious US features, the metastatic nature of a lymph node may be confirmed with measurement of thyroglobulin or calcitonin in the washout of the needle used for UGFNA biopsy (**Grade C; BEL 3**)
- MRI and/or CT is useful in selected cases (**Grade D; BEL 3**)

8. PREGNANCY AND CHILDHOOD

8.1. Thyroid Nodule During Pregnancy

Most cases of thyroid nodules during pregnancy are in patients with preexisting nodules who then become pregnant; occasionally, however, a thyroid nodule is detected for the first time during pregnancy. A thyroid nodule in a pregnant woman should be managed in the same way as in nonpregnant women, except for avoiding the use of radioactive agents for both diagnostic and therapeutic purposes (151,153). Thyroid nodule diagnosis during pregnancy necessitates FNA biopsy if findings are suspicious, regardless of the gestational age of the fetus (193).

Sharing of findings among the endocrinologist, obstetrician, thyroid surgeon, pathologist, and anesthesiologist is recommended. Furthermore, the patient's preferences should also be appropriately considered (62).

8.2. Effects of Pregnancy on Nodular Thyroid Disease

In one series, thyroid nodules were diagnosed in 34 of 221 pregnant patients, who had follow-up through 3 months after delivery (194). The volume of the single or dominant thyroid nodule increased from a mean of 60 mm³ at the beginning of pregnancy to 65 mm³ at the third trimester and to 103 mm³ 6 weeks after delivery. At 3-month postpartum follow-up, the volume was still increased from early in pregnancy (73 mm³). New thyroid nodules developed in 11.3% of women during pregnancy; this circumstance led to an increase in the incidence of nodular thyroid disease, from 15.3% at baseline to 24.4% 3 months after delivery. No new thyroid nodules discovered on US were palpable. These data indicate that pregnancy is associated with an increase in the size of preexisting nodules and with the appearance of newly developed thyroid nodules, possibly because of the negative iodine balance that frequently occurs during pregnancy (195).

8.3. Management and Therapy

8.3.1. Benign Thyroid Nodule

Although pregnancy is a risk factor for progression of nodular thyroid disease, no available evidence indicates

that levothyroxine is effective in decreasing the size or arresting the growth of thyroid nodules during pregnancy (195). Hence, levothyroxine suppressive therapy for thyroid nodules is not advisable during pregnancy.

8.3.2. Follicular or Suspicious Thyroid Nodule

Suspicious cytologic findings pose a difficult problem during pregnancy. Although pregnancy may cause a misleading diagnosis of follicular neoplasm because of a physiologic increase in follicular epithelium, the malignancy rate of follicular neoplasm in pregnant women is similar to that in nonpregnant women—about 14% (196). Therefore, deferring surgical treatment to the postpartum period seems reasonable.

8.3.3. Malignant Thyroid Nodule

Thyroid cancer is rarely diagnosed during pregnancy. If cancer is diagnosed during the first or second trimester, the patient may undergo surgical treatment during the second trimester, when anesthesia risks are minimal (193). However, women with no evidence of aggressive thyroid cancer may be reassured that surgical treatment performed soon after delivery is unlikely to adversely affect prognosis (197). If the cytologic diagnosis is made during the third trimester, the surgical procedure can be postponed until the immediate postpartum period (197).

8.4. Thyroid Nodules in Children

Although no epidemiologic studies on thyroid nodules in children are available, small cohort studies report prevalences of thyroid nodules in prepubertal children of up to 1.8% (198-200). A few small retrospective cohort studies report higher malignancy rates for thyroid nodules in children than in adults: a mean malignancy rate of 26% for operated thyroid nodules in children (201), and 9% to 18% malignant and suspicious results for children undergoing FNA biopsy (201-203). The lower prevalence of thyroid nodules in children, associated with higher malignancy rates than in adults (204), suggests a more frequent surgical approach for thyroid nodules in children.

Diagnostic and therapeutic practice patterns vary considerably for thyroid nodules in children (205). Sensitivity and specificity of FNA biopsy in children are 86% to 100% and 65% to 90%, respectively (15,202), and thyroid US criteria for malignancy seem to have a low predictive value in children (15,206).

Despite a high prevalence of positive lymph nodes and lung metastases at presentation, the prognosis of PTC in children is good (207). Young age is a main determinant of recurrence in children (208). Whereas thyroid carcinomas in children are mostly papillary, several case reports describe follicular thyroid carcinomas in patients with congenital hypothyroidism (195) who also have an increased incidence of thyroid nodules. Moreover, in contrast to

adults, hot nodules in children seem to carry a substantial risk of malignancy (209).

8.5. Key Recommendations

8.5.1. Management of Thyroid Nodules During Pregnancy

- Thyroid nodules in pregnant women should be managed in the same way as in nonpregnant women; in the presence of suspicious clinical or US findings, diagnosis necessitates FNA biopsy (**Grade C; BEL 3**)
- Avoid use of radioactive agents for both diagnostic and therapeutic purposes (**Grade A; BEL 2**)
- During pregnancy, suppressive levothyroxine therapy for thyroid nodules is not recommended (**Grade C; BEL 3**)
- For a growing thyroid nodule during pregnancy, follow-up should include US and FNA biopsy (**Grade C; BEL 3**)
- If FNA biopsy shows a follicular lesion, surgery may be deferred until after delivery (**Grade C; BEL 3**)

8.5.2. Management of FNA Biopsy–Malignant Nodules During Pregnancy

- When a thyroid malignancy is diagnosed during the first or second trimester, thyroidectomy may be done during the second trimester, if recommended. Women with no evidence of aggressive thyroid cancer may be reassured that surgical treatment performed soon after delivery is unlikely to adversely affect prognosis (**Grade C; BEL 3**)
- When a thyroid malignancy is diagnosed during the third trimester, surgical treatment can be deferred until the immediate postpartum period (**Grade C; BEL 3**)

8.5.3. Management of Thyroid Nodules in Children

- Evaluation of nodular disease in children is similar to that in adults (**Grade C; BEL 3**)
- Because of a higher prevalence of malignancy in children, surgery is often necessary for cold, as well as hot nodules (**Grade C; BEL 3**)

9. METHODS

9.1. Development and Use of the Guidelines: Methods of Bibliographic Research

We searched for primary evidence to support the current guidelines by using a “clinical question” method. Each topic covered by the guidelines was translated to a related question. Accordingly, the bibliographic research was conducted by selecting the studies able to yield a methodologically reliable answer to each question.

The first step was to select pertinent published reports. The United States National Library of Medicine Medical Subject Headings (MeSH) database was used as a terminologic filter. Appropriate MeSH terms were identified, and care was taken to select them on a sensitive rather than a specific basis. The MeSH terms and their proper combination enabled us to retrieve the reports pertinent to a specific issue.

The second step was to select relevant published studies. Beginning with the pertinent reports indexed with the appropriate MeSH terminologic filters, we applied the PubMed clinical queries methodologic filters. The clinical queries were grouped into 4 categories: diagnosis, etiology, prognosis, and therapy. For each clinical question, a proper complex search string is available (210,211). From the combination of terminologic (MeSH terms) and methodologic filters (clinical queries), the relevant studies, designed to provide a reliable answer to the question, were selected.

After the relevant published studies had been retrieved, the bibliographic research continued by looking for further evidence cited in the bibliography of each report and by following the Related Articles link listed next to each item in MEDLINE.

Meta-analyses were searched, both in MEDLINE and in the Cochrane Library. Three methods were used to search for meta-analyses in MEDLINE:

- Selection of “Meta-Analysis” from the “Publication Type” menu on the “Limits” tab of the PubMed main page
- Application of function “Find Systematic Reviews” on the “Clinical Queries” PubMed page
- Use of Hunt and McKibbon’s complex string for systematic reviews (200): AND (meta-analysis [pt] OR meta-anal* [tw] OR metaanal* [tw]) OR (quantitative* review* [tw] OR quantitative* overview* [tw]) OR (systematic* review* [tw] OR systematic* overview* [tw]) OR (methodologic* review* [tw] OR methodologic* overview* [tw]) OR (review [pt] AND medline [tw])

The Cochrane Library was browsed by entering free terms in the search window.

Guidelines were searched in MEDLINE and in several guidelines databases. Two methods were used to search for guidelines in MEDLINE:

- Selection of “Practice Guidelines” from the “Publication Type” menu on the “Limits” tab of the PubMed main page
- Use of the following GIMBE-Gruppo Italiano Medicina Basata sulle Evidenze complex string for the guidelines: “guideline” [pt] OR “practice guideline” [pt] OR “health planning guidelines” [mh] OR “consensus development conference” [pt] OR “consensus development conference, nih” [pt] OR “consensus development conferences”

[mh] OR “consensus development conferences, nih” [mh] OR “guidelines” [mh] OR “practice guidelines” [mh] OR (consensus [ti] AND statement [ti])

Guidelines were searched in the following databases: National Guideline Clearinghouse (USA); Agency for Healthcare Research and Quality (USA); Canadian Medical Association—Clinical Practice Guidelines; Canadian Task Force on Preventive Health Care; National Institutes of Health—National Heart, Lung, and Blood Institute (USA); National Health Service Research and Development Health Technology Assessment Programme (UK); National Institute of Clinical Excellence (UK); New Zealand Guidelines Group; PRODIGY Guidance—National Health Service (UK); and the Scottish Intercollegiate Guidelines Network.

9.2. Levels of Evidence and Grading of Recommendations

The AACE protocol for standardized production of clinical practice guidelines was followed to rate the evidence level (EL) of each reference on a scale of 1 to 4 and to link the guidelines to the strength of recommendations on the basis of grade designations A (action based on strong evidence) through D (action not based on any evidence or not recommended) (Table 2) (212). The BEL, corresponding to the best conclusive evidence found, accompanies the recommendation grade (213). All recommendations resulted from a consensus among the AACE, AME, and ETA primary writers and were influenced by input from the Task Force members and reviewers.

Some recommendations were upgraded or downgraded on the basis of expert opinion. In these cases, subjective factors such as clinical experience, cost, risk, and regional availability of specific technologies and expertise took priority over the reported BEL (214).

10. STANDARDS FOR DIAGNOSTIC AND THERAPEUTIC PROCEDURES IN PATIENTS WITH THYROID NODULES

10.1. Ultrasonography

US is the most valuable technique for evaluating thyroid anatomy because it provides accurate information about thyroid size, shape, and texture. In most patients, US examination is considered the criterion standard for detecting nodular thyroid disease; its high resolution currently can distinguish thyroid lesions as small as 1 or 2 mm in diameter. Hence, US examination has a pivotal role in localizing, counting, and measuring palpable and nonpalpable thyroid nodules. Tips for a good US examination are shown in Box 4. US evaluation of nodule margins, shape, texture, and vascularity may provide consistent clues for predicting the probability of malignancy, thus directing patient referral for FNA biopsy.

Table 2
Strength-of-Evidence Scales Reported in the Medical Literature

Category	Description	
Level of Evidence		
1	Well-controlled, generalizable, randomized trials Adequately powered, well-controlled multicenter trials Large meta-analyses with quality ratings All-or-none evidence	
2	Randomized controlled trials; limited body of data Well-conducted prospective cohort studies Well-conducted meta-analyses of cohort studies	
3	Methodologically flawed randomized clinical trials Observational studies Case series or case reports	
4	Conflicting evidence with weight of evidence supporting the recommendation Expert consensus Expert opinion based on experience “Theory-driven conclusions” “Unproven claims”	
Level of Recommendation	Description	Action
A	>1 Conclusive level 1 publications demonstrating benefit >> risk	Action recommended for indications reflected by published reports Action based on strong evidence Action can be used with other conventional therapy or as “first-line” therapy
B	No conclusive level 1 publication ≥1 Conclusive level 2 publication demonstrating benefit >> risk	Action recommended for indications reflected by the published reports Use if the patient declines or does not respond to conventional therapy; must monitor for adverse effects, if any Action based on intermediate evidence Can be recommended as “second-line” therapy
C	No Conclusive level 1 or 2 publication ≥1 Conclusive level 3 publication demonstrating benefit >> risk OR No conclusive risk at all and no benefit at all	Action recommended for indications reflected by the published reports Use if the patient declines or does not respond to conventional therapy, provided there are no significant adverse effects;
Level of Recommendation	Description	Action
D	No conclusive level 1, 2, or 3 publication demonstrating benefit >> risk Conclusive level 1, 2, or 3 publication demonstrating risk >> benefit	“no objection” to recommending their use OR “No objection” to continuing their use Action based on weak evidence Not recommended Patient is advised to discontinue use Action not based on any evidence

Adapted from Mechanick et al (212) and Mechanick et al (213). Used with permission.

Box 4**Ten Tips for a Good Clinical Ultrasonographic Thyroid Examination**

1. Use a good-resolution instrument with digital technology, a 10- to 14-MHz linear probe, and Doppler capability
2. Sit comfortably in front of the ultrasound equipment with the controls within reach
3. Have the patient in a supine position with neck hyperextended
4. Hold the probe firmly in your hand; move it gently and slowly
5. Examine the whole neck from clavicle to jaw
6. Take transverse scans; rotate the probe clockwise to obtain longitudinal images
7. Save images (printouts or digital) of standard projections, plus images of relevant findings. Indicate in each picture the placement of the probe by pictograms or written notes
8. Measure 3 dimensions of nodular findings, using volume calculation for the best reproducibility of serial measurements
9. Be concise but thorough in your report
10. Be mentally neutral: expect unexpected findings

If the thyroid gland is grossly enlarged, the lower portions of both lobes may be located in the mediastinum and thus be partially or totally hidden to US assessment. Thyroid tissue extending behind the trachea also cannot be imaged by US. In these situations CT, MRI, or CT/positron emission tomography is indicated. Thyroid scintigraphy, although offering poor image definition, may be useful in detecting aberrant thyroid tissue such as lingual or thymic ectopia.

10.1.1. Requirements for US Equipment

US examination of the thyroid gland is usually performed with a 10- to 14-MHz linear transducer. Curved transducers may be useful for a large or mediastinal goiter. The US equipment must be adjusted to operate at optimal frequency for clinical use, balancing resolution and beam penetration: deep targets can be evaluated with lower frequencies (5.0-7.5 MHz).

Color-flow Doppler and power Doppler US are highly useful for assessing the general vascularity of thyroid tissue and of single thyroid nodules, providing valuable information concerning their likelihood of malignancy. Doppler imaging is helpful in the evaluation of enlarged lymph nodes, and in the identification of parathyroid adenomas. A needle guide attachment is advisable for US-guided PEI or PLA treatments, to fit the needle exactly within the target under continuous observation during the procedure.

10.1.2. Requirements for US Training

Training programs for thyroid US must include use of US for the whole neck region because thyroid diseases and tumors may extend beyond the anatomic boundaries of the thyroid gland. Most countries have no restrictions on who can perform thyroid and neck US; therefore, it is performed by general practitioners, endocrinologists, radiologists, nuclear medicine specialists, internists, general and

neck surgeons, and others. On one hand, the widespread use of thyroid US allows for enhanced recognition of thyroid nodules and tumors; on the other hand, it may lead to inconsistent use of US equipment and interpretation of US images and inappropriate indications for and performance of FNA biopsies. National scientific societies for radiology, US, and endocrinology are the ideal settings for learning programs.

In the AACE Endocrine Certification in Neck Ultrasound program, the following 6 areas are emphasized:

- (a) Principles of US imaging
- (b) Neck anatomy
- (c) Thyroid pathology
- (d) Parathyroid pathology
- (e) Lymph node pathology
- (f) UGFNA

Minimum requirements for Endocrine Certification in Neck Ultrasound are performance of 100 to 125 US studies (70% diagnostic, 30% UGFNA) in the 12 months preceding certification. Candidates are also required to submit images and reports of diagnostic and UGFNA biopsy procedures. The Italian Society of Ultrasound requires 325 hours of training divided as follows: 20 hours theory; 105 hours tutorial practice in a certified US school in a hospital, university, or research institute; and 200 hours corresponding to 600 US examinations in private or hospital practice. This certification is not restricted to the neck but includes other endocrine glands.

The number of US studies or hours of practice does not automatically guarantee the quality of diagnostic performance. Thyroid US training is effective when the case mix is comprehensive, including different types of tumor cases. The panel suggests the following minimums for expertise in thyroid US: at least 600 US examinations performed per year; at least 30 cases of thyroid tumors, metastatic lymph nodes, and local recurrences evaluated

per year; at least 70% of the thyroid tumors, subsequently diagnosed by FNA biopsy and histology, suspected at first US examination; and at least 150 UGFNA biopsy procedures performed per year, with an inadequate sampling rate of less than 10%.

US is an operator-dependent imaging technique, and static images are unsatisfactory; therefore, endocrinologists should be trained to perform by themselves a complete sonographic evaluation of patients with nodular thyroid disease.

10.1.3. *Thyroid US Method*

The US operator should sit comfortably in front of the screen of the US equipment, having the instrument keyboard at the right height for ease of handling. The patient is placed in the supine position for scanning, usually on the right side of the operator and US machine. A pillow under the patient's shoulders ensures that the neck is adequately hyperextended. A modest amount of gel is squeezed onto the probe footprint and, with the probe, is spread on the patient's neck. The probe is held gently with the right hand, ensuring complete probe contact without applying pressure. Excessive pressure may alter the anatomy and decrease venous blood flow, causing color Doppler mapping distortion.

During the procedure, both thyroid lobes should be imaged in at least 2 projections: axial (transverse) and sagittal (longitudinal) planes. It is advisable to start with a standard axial scan on the right lobe, then slowly rotate the probe 90° clockwise, without uncoupling the transducer from the neck. This method provides unlimited oblique images of the lobe, eventually obtaining the sagittal scan. The same procedure should be repeated on the left lobe. Thyroid images should include transverse scans of the superior, mid, and inferior portions of both thyroid lobes; longitudinal scans of the medial, mid, and lateral portions of both lobes; plus a transverse scan of the isthmus. Lobe size should be recorded in 3 dimensions (anteroposterior, transverse, and longitudinal), and the volume of each lobe may be calculated according to the ellipsoid formula. The thickness of the isthmus on the transverse view also should be recorded. The length and thickness of the thyroid lobes may vary considerably accordingly to body habitus; the more reliable index of thyroid size usually is lobe thickness. A thickness up to 2 cm is considered normal, and greater than 2.5 cm is definitely enlarged.

Thyroid abnormalities should be documented. Small focal alterations, including tiny 2- to 3-mm anechoic colloid areas, isolated calcifications, and reflective bands of fibrous tissue are often seen as part of the normal range of thyroid texture appearance. The location, size, number, and characteristics of nodules should be recorded, including echogenicity (isoechoic, hypoechoic, markedly hypoechoic, hyperechoic, or anechoic), structure (solid, mixed, cystic), margins (regular, irregular, halo), calcifications

(coarse, eggshell, punctate), and vascularity (scanty, normal, high, peripheral, or central). Measurements should be made in 3 dimensions, reporting nodule volume according to the ellipsoid formula. Most US equipment allows automatic volume calculation.

US-assessed volume is the most reproducible indicator of nodule growth during serial clinical evaluations. Nodule thickness and length may change with variations in neck stretching or in probe pressure. Because nodule growth is one of the clinical criteria for recommending a repeated FNA biopsy or surgical excision, the use of a standardized, reproducible method of US measurement is of critical importance in clinical management of thyroid nodules. Significant nodule growth is usually defined as a volume increase of at least 50% or growth in 1 dimension of at least 20%.

US imaging should include the whole neck from clavicles to jaw. Abnormalities of soft tissues adjacent to the thyroid gland, such as abnormal lymph nodes or thrombosed veins, should be documented when encountered. Whenever possible, comparison should be made with previous US or other imaging studies.

Neck examination should be extended to the cervical lymph nodes. Enlarged lymph nodes (>0.5 cm) in the lateral and central compartments of the neck and their US characteristics (hilar line, microcalcifications, cystic necrosis, vascularity) should be studied.

During a US neck study, parathyroid adenomas may be seen incidentally.

10.1.4. *Preoperative US Study of the Neck*

All patients undergoing thyroid surgery should have a preoperative US study. When needed, other imaging studies may be performed (see section 3.6.).

Preoperative US study of thyroid nodules should include the thyroid gland and neck lymph nodes. For surgical planning, the following information should be provided to the surgeon:

- General appearance of the thyroid gland. In particular, coexistent chronic thyroiditis, because this may be associated with fibrosis and difficult gland dissection
- Site, side, and size of the nodule or nodules
- Number of nodules or suspected tumor foci, monolateral or bilateral
- Margins of the nodule, boundaries, suspicious extracapsular extension
- Suspicious lymph nodes in the central and lateral neck compartments
- Coexistent pathologic findings, including enlarged parathyroid gland or other masses

10.1.5. *Color and Power Doppler US Examination*

Color-flow and power Doppler US provide information regarding both the direction and velocity of blood flow.

Power Doppler is currently the preferred technique for assessing nodule vascularity because of its high sensitivity in detecting the slow flows that occur in thyroid nodules. Doppler frequencies should be set to optimize flow detection. A low pulse-repetition frequency of 1 to 1.3 MHz is generally used. The color or power Doppler box should be adjusted on the US screen according to the nodule size and position.

Thyroid nodules are categorized as having absent or present peripheral and intranodular blood flow. Most malignancies have increased central flow, and the finding of increased central vascularity should be reported when encountered. The negative predictive value of power Doppler analysis is low, and a negative study does not eliminate the need for FNA biopsy. Furthermore, the concept of absent or present intranodular flow requires reassessment in light of the increased Doppler sensitivity of newer US equipment. Intranodular blood flow is a generic indicator of viable tissue because it may be detected in virtually any solid nodule. True absence of intranodular vascularity is observed only in cysts, in tumor masses with areas of necrotic degeneration, or in small sclerotic microcarcinomas.

10.1.6. US Reporting

The description of the US characteristics of the thyroid gland should provide all the information useful for clinical purposes. A definite diagnosis is not possible with US, but a mere descriptive report is not helpful if it does not include clinically useful details. Therefore, a US report should enable the reader to classify nodules on a malignancy risk scale.

Specific attention should be paid to several aspects of the US report:

- Aims of the report: Describe the US elements useful for a correct diagnosis and for the patient's knowledge of his or her own situation
- Contents of the report:
 - Thyroid gland: volume, echogenicity, and vascularity
 - Thyroid lesion(s): number of nodules and position within the thyroid gland; size, at least the maximal diameter, specifying whether it is longitudinal, anteroposterior, or laterolateral with respect to the lobe anatomy; echogenicity (anechoic, hypoechoic, isoechoic, or hyperechoic); presence and amount of a fluid component (mixed nodules); characteristics of the borders (regular, irregular, ill-defined) and presence of a peripheral halo; nodule shape ("more tall than wide"); presence of calcifications (micro, macro, egg shell); vascular pattern (presence of peripheral or intranodular flow)
 - Presence of suspicious lymph nodes or US signs suggestive of capsular invasion

- If multiple nodules are present, a general description of the thyroid size and structure may be advisable, pointing out with detail the nodule (or nodules) bearing the US characteristics associated with malignant potential (see section 3.2.), rather than describing the largest ("dominant") nodule

The report should be typewritten and indicate the name of the operator and of the clinic or hospital. It should be stored in an archive or saved in a computerized database; it should be easily retrievable.

Stylistic suggestions for writing the US report:

- Be concise
- Point out the pathologic aspects
- Avoid writing too much about normal findings—describe normality only if a previous pathologic detail is no longer present (such as a cyst that disappeared) or if a normal report is clinically unexpected (for example, a thyroid nodule that is suspected by palpation but that is not shown with US)
- Do not use acronyms, and use technical or easily understandable terms, avoiding words with uncertain or multiple meanings

10.1.7. Documentation

In clinical practice, a standardized sketch of sonographic findings using a scheme of anatomic structures, at minimum, should be provided along with images. A permanent record of the US examination and its interpretation should be available. Images of all appropriate areas, whether normal or abnormal, should be archived along with measurements and labeled with all pertinent information (eg, patient and facility identification, date of examination, side imaged). The exact position of the probe by pictograms should appear on images. Images on printouts and/or digital media (CD-ROM, DVD) should be available along with the final report. US data should be stored and kept in accordance with the clinical needs and with legal and health care facility requirements.

10.1.8. New Technology

The minimum US technology requirements for thyroid and neck examination are digital equipment, a high-frequency (10-14 MHz) linear probe, and color Doppler and power Doppler availability (see section 10.1.1.).

Image resolution and information may be integrated by several other options.

- Sensitive Doppler and B-flow technology. Sensitive and magnified visualization of blood reflectors permits unprecedented studies of nodular blood flow. As mentioned above (section 10.1.5.) the concept of absent or present intranodular flow should be reassessed.

- Tissue harmonics. Additional frequency components over and above the incident frequency (ie, the first harmonic or fundamental frequency) may be detected and imaged (second or tissue harmonic). Tissue harmonics may be useful in detecting deep, ill-defined masses. Typically, tissue harmonics may enhance visualization of central compartment lymph nodes or deep parathyroid glands.
- Extended view. Because of its small parts, the footprint of a linear probe is usually only 3.5 to 4 cm. This restricts the real-time visual field and prevents the visualization of a large mass in a single frame. Systems storing a continuous scan of the field of view can extend the real-time image. Convex and miniconvex probes, with frequencies up to 8 MHz and more, may permit enlarged views, viewing large masses exceeding the linear probe footprint, and exploring the superior mediastinum in large goiters or suspicious metastatic central compartment lymph nodes.
- Compound technology. Speckle noise is generated by rebound of the US beam on a transducer at a 90° angle. In traditional US equipment, thyroid tissues typically appear granular, which sometimes limits or hampers image resolution. Digital compound technology permits acquiring images generated by perpendicular and oblique US beam incidence, typically 90° ± 20°. The combined contributions of standard and steered US beams enable optimization of image quality, obtaining enhanced visualization of borders and interfaces, and smooth speckle noise. True tissue architecture is thus visualized.
- Volume US. Conventional 2-dimensional US images are reconstructed into 3-dimensional images by the operator's brain. The latest real-time 3- or 4-dimensional equipment acquires and constructs the volumetric dataset instantaneously, allowing for coronal, sagittal, and lateral scanning, as well as oblique planes to see anatomic relationships with rotating planes. Volume US is particularly promising in preoperative studies for surgical planning, as well as for evaluating the indications for and the results of minimally invasive ablation techniques.
- Elastography. The basic principle of elastography is that tissue compression produces strain (displacement), which is smaller in harder tissues than in softer tissues. It is scored measuring the degree of distortion of the US beam under the application of an external force, during the real-time US examination. The US elastogram is displayed over the B-mode image in a color scale that corresponds to tissue elasticity.
- Contrast-enhanced imaging. Solutions of gas microbubbles are injected intravenously immediately before US examination. The lack of vascular signal is a useful tool for a precise definition of the size and margins of the area of thyroid necrosis induced by minimally invasive ablation procedures.

10.2. Thyroid Biopsy

FNA biopsy is the most important diagnostic procedure in the initial evaluation of thyroid nodules, and its accuracy influences subsequent clinical management. The use of UGFNA biopsy is strongly recommended because its accuracy in diagnosing thyroid nodules exceeds that of conventional FNA. Because proper FNA biopsy technique and correct smear preparation are critical to ensure good diagnostic results, thyroid biopsy should be performed by experienced operators (see section 4).

10.2.1. Counseling, Informed Consent, and Request Form

The FNA biopsy procedure should be clearly described to the patient beforehand, including reassurance of the absence of any major risks and the possibility of returning safely to work after its conclusion. The patient should be asked to cooperate with avoiding brisk movements, swallowing, speaking, or deep breathing during the procedure. The patient should be reassured that any neck pain during the procedure is transient and that it will be minimized by proper relaxation of the neck muscles.

A consent form should be signed by the patient before the procedure. The document should describe, in an easily comprehensible style, the procedure, the most frequent complications (neck pain, hematoma, skin bruising), and the possibility of a nondiagnostic sample or false-negative or false-positive results.

The request form accompanying the FNA biopsy specimen should include the following information: location of the nodule, size, suspicious or relevant US findings (eg, presence of microcalcifications or a completely cystic lesion), thyroid functional status and autoimmunity, drug treatment, previous radiation therapy, and personal or familial history of thyroid malignancy. Any suspicion of malignancy should always be described.

10.2.2. Procedure for Palpation-Guided FNA Biopsy

Before FNA biopsy is performed, the thyroid gland should be palpated, and the nodule or nodules to be aspirated should be carefully identified. The patient then is placed supine on the examining table with the neck fully extended, supported by a pillow under the shoulders. Adequate lighting should be available. The skin is cleansed with alcohol; local anesthesia is not required. An assistant or a nurse is needed to help with the procedure, prepare and label slides, and apply pressure over the puncture sites.

Commonly available 22- to 27-gauge, 1.5" (3.8 cm) needles attached to a 10- to 20-mL disposable plastic syringe are used. A mechanical syringe holder such as a syringe pistol may be used. The needle is inserted into the nodule without suction, and after the tip is in the nodule, suction is applied while the needle is moved back and forth within the nodule. This maneuver helps dislodge cellular material, which is then sucked into the needle; within a few seconds, the aspirate appears in the needle hub. At that point, suction is released, and the needle is withdrawn. Cytologic smears are prepared by removing the syringe from the needle and filling it with air by retracting the plunger. The needle is then reattached to the syringe, and with the bevel pointing down, one drop of aspirated material is placed on each of several glass slides. Smears are then prepared by using 2 glass slides, similar to those used to make blood smears. Prepared slides can be air-dried or wet-fixed by immediate submersion in 95% ethyl alcohol for Papanicolaou staining.

Some facilities use automated cytology systems, such as Thin Prep (Hologic, Inc, Bedford, Massachusetts), wherein the specimen is placed in the solution for the system and reviewed later in the laboratory. Usually, 2 to 4 aspirations are made from different sites in each nodule; for each aspiration, 2 to 4 slides are prepared. In general, 6 to 12 slides are prepared per biopsy.

Initial sampling may be performed with a 23-gauge needle; larger needles (up to 19 gauge) are used for drainage of a viscous sticky colloid. The use of thinner needles (\approx 27 gauge) without suction should be preferred in a vascularized or complex lesion to minimize blood contamination of the sample. For this nonaspiration (fine-needle capillary) biopsy, the hub of a 25-gauge needle is held in a pencil-grip fashion, the needle is inserted gently into the nodule, and, after aspirate flows into the hub, the needle is withdrawn. Cellular material in the needle shaft is expelled onto glass slides, and smears are prepared as described above.

Immediately after withdrawal of the needle, gentle pressure is applied to the aspiration site (or sites) to prevent hematoma formation. In the absence of problems and if the patient is comfortable, the patient is allowed to leave after a few minutes of observation.

FNA biopsy of a thyroid nodule often causes slight temporary pain and is occasionally associated with a minor hematoma. No serious adverse effects and no distant spreading of tumor cells have been reported. FNA biopsy is relatively safe even with use of aspirin or anticoagulants, but a 5-day withdrawal of aspirin and anticoagulants is recommended.

10.2.3. Procedure for UGFNA Biopsy

UGFNA biopsy, regardless of nodule dimension, provides a significant improvement in the rate of satisfactory

cellular yields for cytologic interpretation compared with the rate for conventional FNA biopsy.

The operator plus a trained assisting nurse are sufficient to perform UGFNA biopsy, provided that needle guides are used. If guides are not used, a sonographer is required who holds the US probe for real-time imaging while the operator is performing UGFNA biopsy.

The room should be large enough to move around the operating bed and all the US equipment. Although the procedure does not require a sterile field, aseptic technique should be used. Therefore, the room should be clean, all materials should be disposable, and sterile gloves, appropriate dressing, and a cap should be worn by the operators.

The US machine should have at least a linear transducer that has a 3.5- to 4.0-cm footprint and multiple frequency settings ranging between 7.5 and 14 MHz, plus Doppler capability. Small curvilinear transducers may be useful for imaging difficult locations, especially in the low neck.

A large adjustable operating table or bed, about 50 cm, is preferable to ease the operator's movements. An auxiliary monitor mounted on a tower is helpful. The monitor should be placed in front of the operator, allowing a straight, comfortable view. A setup tray should be placed well over the patient's legs. The tray should include all materials required for topical cleansing, as well as sterile transducer covers, coupling gel, syringes, and needles. Ten- to 20-mL syringes with a slip-on tip or Luer lock with an eccentric tip that enhances visibility of the syringe hub are preferred, as are bevel-tip needles. The use of spinal or stylet-type needles permits crossing the coupling gel and the thyroid parenchyma while advancing the needle into the lesion of interest and prevents the uploading of gel or thyroid cells into the needle. Moreover, the stylet stiffens the needle, making it easier to maneuver before aspirating the nodule. An assortment of small needles (25- to 27-gauge), medium needles (21- to 23-gauge), and special needles such as the 22-gauge Westcott needle (BD, Franklin Lakes, New Jersey), which has a lateral scraping window for collecting material from hard lesions, should be part of the routine setup. Needle length is variable. Spinal needles inserted through the needle guide should be 75 to 90 mm long. Shorter needles may prevent the use of guide attachment. Pistol grip holders allow the operator to use the left hand to hold the transducer for direct control of the target view and the right hand to fit and move the needle. This procedure enhances the real-time view of the target. A detachable needle guide adapted for the transducer permits the operator to act independently, with the assistance of a nurse.

The operator stands on the left side of the recumbent patient and the nurse or assistant stands on the right. The US equipment is placed on the right side of the patient at head level. The nurse handles the basic US machine switches, such as freeze, depth, gain, color, and power

color adjustments. The operator, in a comfortable standing position, holds the transducer with the left hand and watches images in the auxiliary monitor in front of her or him, aims the guide to the target, and inserts the needle using the right hand.

A 110-cm high bench equipped with glass slides and fixing materials (95% alcohol solution for slide glass immersion or isofix spray) should be available for immediate smearing and fixation. The bench should be illuminated by spotlights for optimal vision during the production of direct smears of aspirated material. If the physician has poor technical skill in slide production, the entire procedure is at risk of inadequacy. This problem may be overcome by diluting material in transport media for subsequent cytopsin or cell block preparations.

Waste boxes to dispose of needles and biologic material should be on hand. Two 4-mL tubes containing 1-mL normal saline solution should be available for hormone measurement in the needle washout (thyroglobulin, calcitonin, parathyroid hormone, other markers).

With UGFNA biopsy, the operator is able to choose the biopsy site on the basis of US evaluation. The recommended biopsy sites are as follows:

- In large nodules, the peripheral part of the lesion is recommended rather than the central area, because of frequent degenerative changes
- In entirely cystic areas, the center of the lesion should be reached to drain the fluid content completely. Cystic fluid should be submitted to the laboratory for evaluation. Most colloid fluids are clear yellow; clear-colorless fluid suggests parathyroid origin, and material should be submitted for measurement of parathyroid hormone. Hemorrhagic fluid suggests increased malignant potential
- In mixed or mostly fluid complex lesions, the needle should be addressed to the root of hubs or pedicles growing into the cystic lumen (the inner area of the pedicle facing the lumen usually contains necrotic debris and cells with degenerative changes). After complete drainage of the fluid, both the solid areas and the peripheral borders of the lesion should be sampled

10.2.4. Hormone Determination on FNA Biopsy Washout

UGFNA biopsy is a sensitive technique for identifying malignant lymph nodes, but 5% to 10% of smears are nondiagnostic.

In patients with lymph node metastatic lesions or local neck recurrence from differentiated thyroid cancer, the combination of cytologic analysis and measurement of thyroglobulin in the needle washout increases the diagnostic sensitivity and specificity of FNA biopsy to nearly 100%. Washout is performed by rinsing the needle with 1 mL of normal saline solution immediately after smear

preparation. In patients with metastatic lymph nodes from differentiated thyroid cancer, thyroglobulin levels before radioiodine ablation are much higher (100-100 000 ng/mL) in the washout than in serum. In patients who have undergone thyroidectomy plus radioiodine therapy and have undetectable serum thyroglobulin levels, US may sometimes detect small suspicious neck recurrences. After radioiodine administration, metastatic lymph nodes may be atrophic and yield nondiagnostic cytology. In these cases, the detection of even low thyroglobulin levels by UGFNA should be considered suspicious for malignancy.

In patients with MTC, measurement of calcitonin in the needle washout with the same technique may aid cytologic diagnosis of the tumoral mass. Calcitonin levels greater than 100 ng/mL by UGFNA should be regarded as suggestive of MTC. This indicator is particularly useful in decision making for patients with borderline serum calcitonin levels, either basal or pentagastrin stimulated. In such patients, the cytologic findings can be nondiagnostic, especially in those with MNG.

Because surgery is the only available cure for MTC, surgical planning for MTC is of particular importance. When metastatic lymph nodes from MTC are suspected on the basis of US examination, either before or after surgery, measuring calcitonin in the UGFNA washout increases the diagnostic sensitivity and specificity of cytologic analysis. Calcitonin levels greater than 50 ng/mL by this method should be regarded as suspicious, and a value greater than 100 ng/mL is nearly diagnostic of metastasis or recurrence of MTC.

During neck US examination for thyroid nodules, parathyroid masses may be detected. Sometimes it is not clear whether these masses are metastatic lymph nodes or parathyroid glands. Cytologic evaluation frequently yields a poor diagnosis in parathyroid adenomas. The washout technique allows measurement of parathyroid hormone from UGFNA and permits the diagnosis of parathyroid adenomas with a near-100% sensitivity and specificity.

10.2.5. LNB and CNB

LNB is a thyroid sampling procedure performed with multiple passes of a large-bore needle (16- to 19-gauge). The slight increase in diagnostic accuracy with LNB, however, is largely outweighed by the need for local anesthesia, the increase in patient discomfort, and the risk of local bleeding. LNB currently has no place in the diagnostic workup of thyroid lesions.

CNB is aimed at obtaining a small tissue sample for histologic evaluation by means of a 19- to 21-gauge, 10- to 12-cm cutting needle that is usually a disposable, spring-activated device. CNB must be performed under US guidance by an experienced operator. Local anesthesia of the subcutaneous and muscle layers of the neck with 2% lidocaine is requested to decrease local pain and discomfort.

For a safe procedure, a longitudinal (craniocaudal) rather than a transverse approach is recommended. With this approach, the needle track never aims toward the large neck vessels or trachea, as could happen with a transverse approach. With the bevel pointed up, the needle is inserted into the lesion under continuous US real-time imaging. The needle tip should never break outside the lesion. Absence of bleeding during insertion should be ensured through US images. After careful placement, the needle is triggered and rapidly extracted. Pressure and an ice pack should be immediately placed on the biopsy site to prevent bleeding.

10.3. Cytologic Diagnosis and Reporting

10.3.1. Preparation of FNA Biopsy Material for Routine Evaluation

In preparing cytologic samples, the selection of a particular technique should be based on the experience of the technical staff, laboratory facilities, and personal preference of the cytopathologist. The appearance of the cytologic details will vary according to the adopted method, but correct processing technique is a prerequisite for a reliable diagnosis. In palpable nodules, the procedure also may be effectively performed by pathologists experienced in thyroid FNA biopsy, which may immediately control the adequacy of smeared specimens.

10.3.1.1. Direct Smears on Slides

This method has been used since the field of diagnostic cytology began and is still the most widely used. Standard diagnostic criteria have been established on the basis of this relatively simple, rapid, and inexpensive method. Artifacts may be produced if excessive pressure is applied to the slides when preparing the smear and if the fixation of material is even slightly delayed, because it prevents a reliable evaluation of nuclear morphology with Papanicolaou staining. Direct smears are essential for immediate on-site interpretation and assessment of sample adequacy.

10.3.1.2. Liquid-Based Cytology

This technique was introduced for automated screening systems for gynecologic samples and was extended to thyroid cytology. The specimen is put into a methanol-based preservative solution and sent to a laboratory where a dedicated machine centrifuges, lyses, and disperses cells. A sample of this cell material is then transferred in a monolayer on a glass slide.

The advantages are ease of use for the clinician, who avoids preparing smears; need to screen only 1 slide; availability of a clear monolayer smear; and possibility of saving material for subsequent ancillary studies. The drawbacks are loss of architectural features; different aspects of the colloid (quality and quantity); decreased evidence of inflammatory cells; and its high cost versus its

effectiveness. Pathologists need dedicated training in this technique because cytomorphology appears different from that on conventional direct smears.

Because of the role of cell architecture and colloid in diagnostic accuracy, liquid-based cytology is not widely used for thyroid FNA biopsy. However, this method may be used as a supplement to direct smears to save the material for possible ancillary studies.

10.3.1.3. Cell Block

The cell block technique refers to cytologic specimens that are processed by paraffin embedding and hematoxylin-eosin staining. The sample is directly immersed in fixative and sent to the laboratory, where it is processed. This method does not require the clinician to prepare the smear and allows sequential sections to be obtained from paraffin blocks for immunohistochemical or molecular studies. Cytomorphologic details in these samples, however, are different from those observed in direct smears. For this reason, the cell block technique does not replace cytologic smears but is an additional resource for possible ancillary investigations. A dedicated sample of cytologic material for cell block preparation is recommended.

10.3.2. Classification Schemes for Cytologic Diagnosis

The main goal of thyroid FNA biopsy is to distinguish patients who may benefit from medical treatment from those who should undergo surgery. The cytologic report should be descriptive, but, whenever possible, a diagnosis should be made. A numeric code should be added identifying the category of lesion for risk of malignancy and therapeutic options.

Currently, several classification schemes are used for cytologic diagnosis of thyroid lesions. The 4-category 2006 American Thyroid Association and AACE/Italian Association of Clinical Endocrinologists classifications combine in 1 class both follicular lesions that are mostly benign but that cannot be definitely diagnosed on cytologic grounds and nodules suspicious for malignancy, which are primarily carcinomas on definitive histologic evaluation. Because the risk of malignancy is quite different in these 2 types of lesions, it seems inappropriate to combine them, with a similar risk evaluation and the same operative recommendation (surgery without frozen section evaluation). In contrast, the National Cancer Institute's proposal of splitting the former "indeterminate" category into 3 new classes (follicular lesion, follicular neoplasm, and suspicious for malignancy) is accurate, but its widespread use may not be easy in nonspecialized centers because of its relative complexity and the lack of clear-cut cytologic criteria for distinguishing follicular lesions from follicular neoplasms.

We propose the use in clinical practice of 5 cytologic diagnostic categories, as a trade-off between a simpler but

less accurate 4-class scheme and the more accurate 6-class categorization that may be more difficult to use (Tables 3 and 4).

10.3.2.1. Class 1: Nondiagnostic

“Nondiagnostic” reports should not exceed 15% of FNA biopsy samples. They can be classified as inadequate (presence of processing problems), insufficient, or both. A sample is *inadequate* when biased by smearing, fixing, or staining errors, whereas a sample is defined as *insufficient* (or nonrepresentative) when the number of cells collected from the lesion is insufficient for a definite diagnosis. The pathologist should indicate the inadequacy or insufficiency of the sample and the possible causes in the cytologic report.

A sample correctly smeared, fixed, and stained is defined as *adequate*. Although the evaluation of adequacy is difficult to standardize, a sample with at least 6 groups of 10 to 20 well-preserved epithelial cells from the lesion is considered sufficient.

Some insufficient cases may be included in the benign category (class 2) in specific clinical settings, such as samples with:

- Presence of abundant and homogeneous colloid with scattered thyrocytes or follicular cells aspirated from colloid nodules or cysts, if the lesion lacks a solid component or the nodule collapses after aspiration

- Presence of lymphocytes only, in clinically and US-diagnosed Hashimoto thyroiditis
- Presence of red blood cells, necrosis, and macrophages from hemorrhagic pseudocysts

If, however, the sample contains only a few cells that demonstrate unambiguous neoplastic features, the sample is not considered insufficient and should be classified as suspicious (class 4).

If a solid part remains after drainage of a cystic lesion, it should be immediately reaspirated. US guidance is needed to guide the needle into the solid component of the nodule.

Operative suggestion:

- Perform a repeated FNA biopsy at least 1 month after the previous procedure, according to the clinician’s opinion
- Always use UGFNA biopsy

10.3.2.2. Class 2: Benign

This category usually accounts for 60% to 75% of the cytologic reports. It includes colloid goiter, hyperplastic nodule, autoimmune (Hashimoto) thyroiditis, and granulomatous (de Quervain) thyroiditis.

Operative suggestion:

- Follow-up clinically and with US
- Repeat FNA biopsy, according to the clinician’s or cytopathologist’s judgment, to decrease false-negative results

Table 3
AACE/AME/ETA Classification for Cytologic Diagnosis of Thyroid Nodule^a

Diagnostic Category	Suggested Action
Class 1. Nondiagnostic (inadequate-insufficient)	Repeated US-guided FNA biopsy, unless pure cyst
Class 2. Benign (non-neoplastic)	Clinical and US follow-up FNA biopsy repetition if nodule size increases or according to clinician’s or cytopathologist’s judgment
Class 3. Follicular lesion/neoplasm	Surgery for most Frozen section usually not recommended In some cases follow-up on the basis of a multidisciplinary team evaluation
Class 4. Suspicious	Surgery Frozen section recommended
Class 5. Positive for malignant cells	Repeated FNA biopsy only if more material is needed Surgery for differentiated carcinomas Further diagnostic workup for anaplastic carcinomas, lymphomas, and metastatic lesions

Abbreviations: AACE, American Association of Clinical Endocrinologists; AME, Associazione Medici Endocrinologi; ETA, European Thyroid Association; FNA, fine-needle aspiration.

^a This proposed classification is based on the results of the British Thyroid Association Thyroid Cancer Guidelines (2002-2006) (62) and the Italian SIAPEC-IAP Working Group for the Consensus on Classification of Thyroid Cytology (2008) (63).

Table 4
Summary of Current Classification Schemes for Cytologic Diagnosis on the Basis of Thyroid Fine-Needle Aspiration Biopsy^a

AACE-AME, 2010	ATA, 2006	BTA, 2007	NCI, 2008
1. Nondiagnostic	Nondiagnostic/inadequate	Nondiagnostic	Unsatisfactory
2. Benign	Non-neoplastic	Benign	Benign
3. Follicular lesion	Indeterminate	Follicular lesion	Follicular lesion Follicular neoplasm
4. Suspicious		Suspicious	Suspicious
5. Malignant	Malignant	Malignant	Malignant

Abbreviations: AACE, American Association of Clinical Endocrinologists; AME, Associazione Medici Endocrinologi; ATA, American Thyroid Association; BTA, British Thyroid Association; NCI, National Cancer Institute.

^a Data from references 62-64.

- Always perform a repeated UGFNA biopsy in case of nodule growth or suspicious US findings and in relapsing cystic lesions

10.3.2.3. Class 3: Follicular Lesion

This category encompasses all follicular-patterned lesions: adenomatoid hyperplasia, adenoma, follicular carcinoma, oxyphilic cell lesions, and some cases of the follicular variant of PTC. In these cases, only histologic examination (and not cytology alone) provides a diagnostic conclusion. This category usually accounts for 20% of thyroid cytologic reports.

At histologic examination, about 80% of the class 3 diagnoses are benign lesions, whereas only 20% of them are malignant tumors.

Evaluation of some immunohistochemical markers, such as galectin-3, HBME-1, and cytokeratin 19, may improve the accuracy of the cytologic diagnosis. Although they do not have definitive predictive value, they can be used as an aid to determine the few cases that can be followed up without surgery. The molecular markers PPARgamma and Ras have shown promise, but larger studies are needed to prove their efficacy.

Some cases characterized by cytologic alterations that are too mild to be included in the class 4 category (suspicious), but that are too marked to be included in the benign category (class 2), may be designated class 3. The choice of including such samples in the “follicular lesion” category must be supported by an adequate description in the report.

Operative suggestion:

- Perform surgical excision and histologic examination of the lesion in most cases
- Consider clinical follow-up without immediate diagnostic surgery in cases with favorable clinical, cytologic, and US features

- Provide information about the uncertain nature of the nodule to the patient
- Do not obtain frozen section

10.3.2.4. Class 4: Suspicious

This category includes (a) samples with cellularity characterized by cytologic features suggesting malignancy but that do not fulfill the criteria for a definite diagnosis and (b) samples with insufficient cellularity but with cellular features strongly suggesting malignancy.

Most cases are determined to be PTC on definitive histologic analysis. This class accounts for about 5% of cytologic diagnoses.

Operative suggestion:

- Perform surgery with intraoperative histologic examination
- Perform a repeated FNA biopsy, according to the clinician’s or cytopathologist’s opinion, if more material is needed for ancillary studies (eg, immunocytochemistry, molecular studies, or flow cytometry)

10.3.2.5. Class 5: Malignant

All cases with a diagnosis of malignant neoplasm (papillary, medullary, and anaplastic carcinoma; lymphoma; and metastasis) are included in this category. It accounts for 5% to 15% of cytologic diagnoses. The report should contain an adequate cytologic description.

Operative suggestion:

- Perform surgery for differentiated carcinomas
- Plan the surgical approach according to the clinical setting and imaging findings
- Perform further diagnostic workup before surgery for anaplastic carcinomas, lymphomas, and metastatic lesions

10.3.3. Additional Studies

With the application of gene analyses to FNA biopsy material, it is possible to identify several specific gene alterations (eg, in p53, Ras, met, erb2, retinoblastoma, p27, cyclin D1), but these are not yet used in daily cytologic practice. However, some mutations (eg, *RET* in MTC) or gene alterations (eg, *RET* and *BRAF* in PTC) currently can be investigated in FNA biopsy material. To date, only histochemistry (Congo red stain for amyloid) and immunohistochemistry are widely used techniques. These techniques can be easily applied to smears (either fresh or destained) or cell blocks. An important drawback of immunohistochemistry is the risk of false-positive interpretations due to detection of endogenous biotin, particularly in oncocyctic (oxyphilic) cell lesions. However, procedures based on a biotin-free detection system block endogenous biotin reactivity and generally provide reliable results.

Immunocytochemical markers are indicated for diagnostic purposes, but they are not yet used routinely as prognostic or therapeutic markers (eg, cell cycle proteins, oncogenes, receptors).

Calcitonin, carcinoembryonic antigen, and chromogranin A are useful MTC markers. Pancytokeratin is helpful to distinguish anaplastic carcinoma from sarcomas and lymphomas. Flow cytometry or immunocytochemical detection of the different lymphocytic lineage markers may assist in the characterization of non-Hodgkin lymphomas. Parathyroid hormone reactivity identifies intrathyroidal nodules of parathyroid origin. Finally, thyroglobulin and thyroid transcription factor 1 are useful initial markers in the diagnostic workup of suspected metastasis to the thyroid (excluding those of lung origin). A peculiar Ki67 reactivity pattern at the membrane level is specifically reported in hyalinizing trabecular tumor and may be useful for distinguishing this rare tumor from the more common PTCs and MTCs that may share both nuclear and architectural features with hyalinizing trabecular tumor.

The topic of follicular (or indeterminate) cytology (follicular-patterned nodules including follicular adenoma, follicular carcinoma, and the follicular variant of PTC) has been the subject of numerous studies exploring the sensitivity and specificity of different markers of malignancy of follicular thyroid tumors. The results are still controversial, but no single marker is specific and sensitive enough to replace the conventional morphologic diagnosis of "indeterminate follicular neoplasm." The most common and explored markers of follicular tumors include: (a) the fusion gene product PAX8-PPAR γ (expressed by follicular carcinoma but not by adenoma nuclei); (b) HBME-1 (a marker of mesothelial cells and tumors, which is overexpressed by thyroid follicular and papillary carcinomas); (c) thyroid peroxidase; (d) cytokeratin 19 (strongly expressed in PTC as opposed to benign lesions); (e) *RET* (gene rearrangements are markers of some PTCs); and (f) galectin-3 (a β -galactoside-binding lectin, widely distributed in

human macrophages, endothelial cells, and several epithelia, including those of malignant follicular-derived thyroid tumors).

Since none of the above markers are 100% sensitive and specific, a panel of markers may provide the highest diagnostic accuracy in cytologic diagnosis. The combination of HBME-1, cytokeratin 19, and galectin-3 seems to provide the highest sensitivity and specificity in thyroid lesions. The demonstration of a *BRAF* mutation is of relevant importance for clinical management of a thyroid lesion because it confirms the presence of PTC and may predict an aggressive tumor.

10.4. Laboratory Standards

10.4.1. Thyrotropin

Baseline serum TSH determination is the single best test of thyroid status. The use of anti-TSH monoclonal antibodies eliminates cross-reactivity with other glycoprotein hormones. Pituitary extracts used for assay standardization (Medical Research Council 80/558) contain various TSH isoforms, but the isoforms that circulate in the blood may be different from those used for calibration of the assay. The different abilities of the antibodies used in TSH assays to detect these various isoforms may be the basis of assay bias. Moreover, falsely high results can be caused by heterophilic antibodies. Interference can be ruled out by measuring TSH concentration in the sample specimen using the method of a different manufacturer and checking for discordance between the 2 results.

In samples with TSH concentrations less than 0.2 mIU/L, different methods may give different results. The functional sensitivity indicates the concentration showing a 20% between-run coefficient of variation. Laboratories should use a reliable and sensitive method for measuring TSH with a functional sensitivity of less than 0.02 mIU/L. Because some but not all commercial methods have a functional sensitivity less than 0.02 mIU/L, it is mandatory that each laboratory report contains detailed and clear information about the method used by the laboratory and its functional sensitivity. This information helps the clinician to better evaluate the accuracy of the reference intervals provided by the manufacturer, because in some cases a reference interval inconsistent with the characteristics of the method may be reported.

10.4.2. Plasma Total Thyroxine and Total Triiodothyronine

Increase or decrease in serum thyroid hormone-binding proteins will result in changes in total thyroxine or triiodothyronine values, or both. Therefore, measurement of total thyroid hormones in serum is of limited clinical value.

10.4.3. Free Thyroxine and Free Triiodothyronine

Free thyroid hormones, unaffected by binding proteins, make up the active portion of the total pool of

thyroid hormones. In practice, measurement of free thyroxine and free triiodothyronine is a more reliable test of thyroid function than measurement of total hormone levels. Nevertheless, free thyroxine and triiodothyronine measurements are fraught with technical problems, and results must be interpreted cautiously. Free thyroxine measurement by equilibrium dialysis is more reliable but technically demanding and is not performed routinely by commercial laboratories.

Because of the problematic nature of free hormone measurement, laboratories should (a) obtain from kit manufacturers information regarding both the effect of sample dilution on the free hormone assay and how the kit assay compares with equilibrium dialysis; (b) acknowledge differences in assay performance in different situations such as during pregnancy, with nonthyroidal illness, and with use of some medications such as heparin, phenytoin, furosemide, carbamazepine, and salicylate; and (c) inform endocrinologists about the limitations of the method.

10.4.4. Anti-Thyroid Peroxidase Antibodies

Many assays for thyroid peroxidase are now standardized against the World Health Standard National Institute for Biological Standards and Control 66/387. A set of calibrators can be used to construct a curve for calculation of antibody values (in IU/mL) and is used as the reference for establishing the concentrations of the calibrators.

TPOAb can be detected using complement fixation, agglutination test, or by immunofluorescence on thyroid tissue sections, but concentrations are most commonly estimated using enzyme-linked immunosorbent assay or other sensitive and specific (manual or automated) immunoassays.

Functional sensitivity should be determined for TPOAb. Clinicians and laboratorians should recognize that TPOAb results are method dependent.

10.4.5. Antithyroglobulin Antibodies

Antithyroglobulin antibodies interfere with the accurate measurement of serum thyroglobulin. Iodination of thyroglobulin may alter the epitope-binding patterns, and this results in multiple naturally occurring molecular configurations that are compatible with adequate hormone synthesis (ie, iodination of thyroglobulin results in conformational changes in the molecule and the antigenic epitopes). The epitope specificity of the antithyroglobulin antibody methods used for patients with thyroid cancer should be broader than the restricted epitope specificity typically associated with autoimmune thyroid disease. Assays for antithyroglobulin antibodies include simple hemagglutination techniques, immunofluorescence on thyroid tissue sections, enzyme-linked immunosorbent assays, and radioimmunoassays. Serial antithyroglobulin antibody monitoring necessitates the use of the same method each time, because assays vary in sensitivity, specificity, and absolute values

despite claiming standardization against the International Reference Preparation MRC 65/93.

10.4.6. Anti-TSH Receptor Antibodies

Two methods are used for estimation of TRAb concentrations. One is a bioassay based on cultured cells to measure the stimulating antibodies, and the other involves a receptor assay based on the measurement of ¹²⁵I-labelled TSH. Radioreceptor assays using isolated, solubilized, or, more recently, recombinant human TSH receptor have been used to develop thyroid-binding inhibition immunoglobulin assays that detect both classes of antibody (stimulating and blocking).

Intermethod differences for TSH-binding inhibitory immunoglobulin methods are wide, and the interassay precision is so poor (coefficients of variation ≈20%) that it is difficult to compare values from different methods.

The antibodies measured using these commercial methods that quantify the inhibition of TSH binding to porcine or human TSH receptors are referred to by different names, including thyroid-binding inhibiting immunoglobulins and TRAbs. The assays do not distinguish between stimulatory or blocking properties of the antibodies. Only a few research laboratories offer assays that assess the stimulating ability of TRAbs by quantifying cyclic AMP production in cultured thyrocytes or cell lines that express the TSH receptor.

10.4.7. Thyroglobulin

Marked bias differences occur among thyroglobulin assays, with an up to 4-fold difference between the highest- and lowest-biased assays. Assays for thyroglobulin should be standardized using the International Standard Certified Reference Material 457. Thyroglobulin values measured by immunometric methods have more pronounced variation than those determined by radioimmunologic methods. This difference is probably due to the use of polyclonal antibodies with a broad epitope specificity for radioimmunologic determinations. This enables them to measure a wider range of abnormal tumor-derived thyroglobulin isoforms than immunometric assay methods that use monoclonal antibodies with a limited epitope specificity.

The use of a reference range derived from normal subjects is not recommended. The laboratory should ensure that users are aware that patients receiving thyroxine suppressive therapy should ideally have a thyroglobulin value less than 2 µg/L or a bias-adjusted cutoff as advised by the laboratory. Laboratories and manufacturers should determine and quote the minimum detection limit of their thyroglobulin assay on the basis of functional sensitivity derived from patient samples. The minimum detection limit should ideally be 0.2 µg/L or less. It is important that the laboratory is consulted to determine the appropriate bias-adjusted cutoffs for use in clinical practice.

Laboratories and manufacturers should identify the analytical range of their thyroglobulin assay and adopt procedures to identify samples with “hook effects.” They should inform clinicians of the possibility of interference due to endogenous antithyroglobulin antibodies and should indicate the nature of the possible interference (false increase or decrease in measured thyroglobulin).

Identification of possible assay interference is best achieved using either antithyroglobulin antibody measurements or the discordance between the thyroglobulin results obtained using both immunometric assays and radioimmunoassays. Recovery experiments alone are not recommended to identify assay interference.

For any thyroglobulin method, it is appropriate to make available the results of a clinical assessment of the assay performance. The clinical sensitivity and specificity (ie, positive and negative predictive values) of the assay should always be quoted.

10.4.8. Calcitonin

Calcitonin assays should be standardized using World Health Organization International Standard IS 89/620, and laboratories can choose whether to use a method that recognizes primarily monomeric calcitonin (immunometric assay) or a method with broader specificity (radioimmunoassay).

Laboratories should quote the minimum detection limit of their assay on the basis of a precision profile derived from patient samples. For any method of measuring calcitonin, the results of a clinical assessment of assay performance should be available. The clinical sensitivity and specificity of the assays should be quoted.

Although calcitonin is a marker for MTC, calcitonin levels may also be increased, although infrequently, in other clinical conditions such as C-cell hyperplasia, pulmonary and pancreatic neuroendocrine tumors, renal failure, and hypergastrinemia (use of proton-pump inhibitors). Higher calcitonin levels are measured in males. Depending on the method used, smoking may either increase or decrease calcitonin concentration.

On the basis of the above considerations, slightly increased levels of calcitonin should be verified by a pentagastrin stimulation test, but this, unfortunately, is not universally available. Pentagastrin (Cambridge Laboratories, Cambridge, United Kingdom), 500 µg/2 mL vials, should be administered at a dose of 0.5 µg/kg by rapid intravenous injection. Blood samples should be drawn at baseline and 2, 5, and 15 minutes. Calcium infusion, although less sensitive than pentagastrin, is a practical and attractive alternative.

10.5. Radioiodine Treatment

The amount of radioiodine to be administered can be fixed (300–1800 MBq), without any dose calculation or adjustment, on the basis of clinical criteria such as goiter size

or uptake determination. This approach is simple, minimizes cost, and performs no worse than using a cumbersome calculation method. Alternatively, an individual computation of the desired concentration of radioiodine (2.96–7.4 MBq/g) or of retained radioactivity (300–400 Gy) at the target (ie, autonomous tissue) can be performed. For absorbed dose estimation, the following formula can be used:

$$A_0 = 5829 \times ([DT \times m] / [U_{\max} \times T_{1/2}^{\text{eff}}])$$

where A_0 = administered activity of ^{131}I (MBq); DT = prescribed absorbed dose (cGy); m = autonomous tissue mass (g); U_{\max} = maximal thyroid uptake (%); and $T_{1/2}^{\text{eff}} = ^{131}\text{I}$ effective half-life in target tissue (h).

Maximal thyroid uptake and effective half-life are measured as tracer activity after administration of ^{131}I , and the target volume can be estimated by US or thyroid scan. In cases of multifocal autonomy, the thyroid gland as a whole can be used as the target volume, and the desired absorbed dose decreased to 150 to 200 Gy.

Personalized approaches can decrease the number of ineffective treatments or help to avoid administration of too much radioiodine, but individualizing therapy is more complex and expensive. Neither approach has been proved definitively superior to the other. Radioiodine therapy is usually defined as successful when the posttreatment TSH value exceeds 0.5 IU/mL. Technetium thyroid uptake under suppression can also be used to evaluate the success of radioiodine treatment. If hyperthyroidism is not definitively cured, radioiodine treatment can be repeated after 3 to 6 months.

Until approval by the United States Food and Drug Administration, the use of rhTSH to augment radioiodine treatment of MNG is considered off label. Its use should be considered in elderly patients or in those with comorbid conditions that preclude anesthesia and surgical treatment.

Radioiodine should not be used if the presence of a malignant lesion is suspected, and UGFNA biopsy should precede treatment.

Treatment of patients with an adrenergic blocking agent or calcium-channel blocker during ^{131}I treatment should be considered. After treatment, patients should undergo follow-up for the development of hypothyroidism or hyperthyroidism.

10.6. US-Guided Interventional Procedures

10.6.1. PEI of Cystic Lesions

For PEI, a real-time US system with a 7.5- to 14.0-MHz probe, 95% sterile ethanol, a spinal needle, and a disposable plastic syringe are needed. A 22-gauge, 75-mm spinal needle is used because it is a flexible needle, is fitted with a mandrel, and is long enough to cross the steering device and reach deep thyroid nodules. Guidance devices may be helpful, but experienced operators may prefer

manual needle placement to fit needles according to the variable anatomy of the nodule and the neck.

Near-complete fluid removal is performed to facilitate clear visualization of the needle in the cavity. Without removal of the needle, a syringe containing ethanol is substituted for the aspirating syringe. The ethanol is slowly injected in amounts of 1 to 10 mL, depending on the volume of the aspirated fluid. PEI can be performed by 1 operator, inserting the needle through a guiding device connected to the probe, or by 2 operators, one handling the probe and the other the needle.

PEI is performed on outpatients; the procedure is rapid (not exceeding 10 minutes) and no general anesthesia is needed. There is no evidence that the serum ethanol level increases after PEI, so the patient can drive after the procedure. There is no need for a sterile field, but aseptic technique and disposable items should be used.

The procedure should be performed by experienced operators with adequate training. Adverse effects of PEI are generally mild and transient. Local infiltration with lidocaine 2% (2-4 mL), best seen under real-time US imaging, generally prevents local pain. Should mild local pain occur, it can be controlled with low doses of nonsteroidal anti-inflammatory drugs for 1 to 2 days.

Transient dysphonia is quite rare after PEI treatment of cystic lesions. Real-time US monitoring during PEI allows verification of the correct position of the needle tip within the nodule and assessment of the distribution of the injected ethanol, which is recognizable as an expanding hyperechoic area within the cystic cavity. Ethanol seeping outside the cystic nodule is always attributable to incorrect procedure (usually the displacement of the needle tip) and may induce chemical damage to the recurrent laryngeal nerve. If unilateral vocal cord paresis is confirmed with laryngoscopy, corticosteroid therapy (betamethasone, 1.5 mg daily) can be administered for a few days. The patients should be reassured that, in most cases, a complete recovery from vocal cord paresis usually occurs within 1 to 2 months.

In patients with thyrotoxicosis (rare in cystic AFTN), the procedure may be followed by transient exacerbation of thyrotoxic symptoms. In most cases, only a slight, transient, and asymptomatic increase in serum thyroid hormone levels is observed.

Subcutaneous and intracapsular hematomas are rare and self-resolving complications. Antiplatelet agents and anticoagulants should be withdrawn before PEI to ensure normal coagulation tests.

10.6.2. Thermal Ablation Procedures

10.6.2.1. Percutaneous laser thermal ablation

PLA is a minimally invasive procedure proposed as an alternative to surgical ablation of benign thyroid lesions causing compressive symptoms or cosmetic concerns. The

flat-tip technique is based on inserting a 300- μ m plane-cut optic fiber through the sheath of a 21-gauge Chiba needle and placing the bare fiber in direct contact with thyroid tissue for a length of 7 to 10 mm, according to the size of the lesion. Fiber locks allow the tip of the fiber to remain still inside the lesion for the appropriate time. A single optic fiber, maintained in a still position, destroys only a small amount of tissue (about 1 mL) when an energy of 1600 to 1800 J is delivered with an output power of 2 to 4 W. Therefore, simultaneous insertion of multiple fibers is generally needed. Parallel insertion of 2 to 4 fibers allows an ellipsoid ablation, suitable for the ellipsoid shape of most benign thyroid nodules. This multiple parallel fiber technique obtains ablation diameters of up to 40 to 45 mm wide and 18 to 22 mm thick. Fiber pull-back from the bottom toward the upper part of the nodule, along the craniocaudal axis, achieves further tissue destruction. A maximum of 30 mL of nodular tissue may be destroyed in a single session.

Anticoagulants or antiplatelet drugs should be withdrawn before the PLA procedure to allow for normal coagulation tests. PLA is an office-based procedure, but precautions should be established for patient safety. A multiple-channel monitor showing vital functions is connected to the patient. A venous catheter is inserted in a peripheral forearm vein to ensure continuous venous access. Emergency care facilities and materials, including a defibrillator, should be on hand in the operating room, and an anesthesiologist should be available in case of emergency.

A sterile operative setting is arranged, and the operator and assistants are dressed with sterile disposable coats, masks, caps, and laser-protection glasses. A sensitive color Doppler US machine is required, equipped with 7.5- to 15-MHz multifrequency linear probes with a 3.5- to 4.5-cm footprint. The patient is placed on the adjustable operating bed in the supine position with neck hyperextended. For the patient's comfort, pillows are placed under the shoulders and back. Patients wear laser-protection glasses. Light sedation is obtained with intravenous diazepam (2-3 mg, repeatable during the procedure if necessary). Local anesthesia with lidocaine subcapsular and subcutaneous infiltration is performed under US assistance with thin needles (29- to 30-gauge). Sedation decreases patient anxiety, swallowing, cough, and other untoward movements. Local analgesia prevents or minimizes local discomfort and pain.

Chiba needles (21-gauge), up to 4 simultaneously, are inserted along the craniocaudal nodule axis in parallel planes at a distance of 8 to 10 mm. Guidance devices may be helpful. However, experienced operators may prefer manual needle placement to fit needles according to the variable anatomy of the nodule.

Accurate needle placement is critical for procedure success and prevention of adverse effects. After needle placement, stylets are removed, fibers are inserted through the needle sheath into the nodule, and laser firing starts. A continuous, real-time, US view, with axial, longitudinal,

and multiplanar scans, is ensured by having an expert sonographer assist the operator. A highly echogenic area resulting from tissue heating and vaporization slowly enlarges over time. Appropriate energies (500-700 J/mL with mean output power of 3 W) are delivered in 10 to 30 minutes. The laser is switched off and, at the same time, the fibers and needle are extracted. At the end of the procedure, an oval-shaped hypoechoic area shows the zone of presumed tissue ablation, and no blood flow is observed inside the destroyed tissue. The ablation area can be seen more definitively by US several hours or the day after the procedure, after the vapors infiltrating the tissue have disappeared.

Necrotic tissue will be reabsorbed over several months after PLA, with consequent nodule shrinkage proportional to the amount of destroyed nodular tissue. After PLA intervention, most patients are able to leave the operating room without assistance. However, because of residual sedation, they must wait in the recovery room for a few hours, and before going home they are checked clinically and by US examination.

Pain may be the principal adverse effect after PLA. Local anesthesia prevents pain during needle fitting and laser exposure. Pain after the procedure is minimized by immediate intravenous administration of 20 mg methylprednisolone and 100 mg ketoprofen. Intranodular bleeding during needle fitting should not prevent PLA because laser firing stops the bleeding. Rare subcapsular hematomas are spontaneously reabsorbed in 2 weeks. Skin burn is due to an incorrect procedure with excessive fiber pull-back and subdermal heating. Swelling due to colliquation of the ablated nodule may occur uncommonly after 1 to 2 weeks if high energies with multiple needles have been used. In these cases, drainage ensures immediate relief. Accurate procedure, allowing at least 7 mm between fiber tip and the trachea/cricoid cartilage corresponding to the recurrent laryngeal nerve position, guards against nerve damage and vocal palsy. Late vocal palsy, occurring minutes or hours after PLA, is extremely rare. It is due to nodule swelling and pressure on the laryngeal nerve and is reversible in 4 to 6 weeks with corticosteroid treatment. Immediately and for 7 to 10 days after the PLA procedure, the nodule swells by an average of 7% due to edema and may cause a sense of pressure spontaneously subsiding. Beginning the day after PLA, patients receive prednisone 25 mg for 3 days and 5 mg for 4 days. Proton-pump inhibitors (lansoprazole 30 mg) are simultaneously administered for 10 days.

The mean TSH level decreases and free thyroxine increases the day after PLA, returning to baseline within 1 to 3 months. Antithyroglobulin antibody and TPOAb levels may increase in some patients, returning to baseline in a year. These laboratory changes are not symptomatic.

10.6.2.2. Other Thermal Ablation Procedures

RFA has been proposed for the debulking of large benign thyroid nodules. RFA is based on percutaneous insertion of large needle electrodes (14-18 gauge) or hook needles and is usually performed with local anesthesia or under conscious sedation. A high-frequency electrical current moves from the electrodes into the tissues, and the alternate movement of ions results in frictional heating of the target tissue. Monopolar probes produce heat by ionic agitation within a 2-mm radius; tissue heating beyond this zone is due to heat conduction.

Due to the cost of the device, the cumbersome technique, and the absence of prospective randomized trials, RFA is currently not recommended in the routine management of thyroid nodules.

Highly focused US ablation was proposed for the debulking of thyroid nodules in experimental models. Ultrasound energy is focused through the skin, achieving precise destruction of small sections (2 × 2 × 10 mm) of the target tissue. The procedure is noninvasive and allows continuous on-line US targeting. The technique has not yet been tested in controlled clinical trials.

ACKNOWLEDGMENT

AACE/AME/ETA Task Force on Thyroid Nodule Committee Members include the listed authors and Sofia Tseleni Balafouta, MD; Zubair Baloch, MD; Anna Crescenzi, MD; Henning Dralle, MD; Roland Gärtner, MD; Rinaldo Guglielmi, MD; Jeffrey I. Mechanick, MD, FACP, FACN, FACE; Christoph Reiners, MD; Istvan Szabolcs, MD, PhD, DSc; Martha A. Zeiger, MD, FACS; and Michele Zini, MD.

DISCLOSURE

Primary Authors

Dr. Hossein Gharib reports that he does not have any relevant financial relationships with any commercial interests.

Dr. Enrico Papini reports that he does not have any relevant financial relationships with any commercial interests.

Dr. Ralf Paschke reports that he has received speaker honoraria from Merck & Co, Inc, and sanofi-aventis U.S., LLC.

Dr. Daniel S. Duick reports that he has received speaker honorarium from Genzyme Corporation.

Dr. Roberto Valcavi reports that he does not have any relevant financial relationships with any commercial interests.

Dr. Laszlo Hegedüs reports that he has received consultant honoraria and research grant support from Novo Nordisk A/S and Genzyme Corporation and consultant and speaker honoraria from Theraclion.

Dr. Paolo Vitti reports that he does not have any relevant financial relationships with any commercial interests.

AACE/AME/ETA Task Force on Thyroid Nodules

Dr. Sofia Tseleni Balafouta reports that she does not have any relevant financial relationships with any commercial interests.

Dr. Zubair Baloch reports that he has received consultant honorarium from Veracyte, Inc.

Dr. Anna Crescenzi reports that she does not have any relevant financial relationships with any commercial interests.

Dr. Henning Dralle reports that he does not have any relevant financial relationships with any commercial interests.

Dr. Roland Gärtner reports that he does not have any relevant financial relationships with any commercial interests.

Dr. Rinaldo Guglielmi reports that he does not have any relevant financial relationships with any commercial interests.

Dr. Jeffrey I. Mechanick reports that he does not have any relevant financial relationships with any commercial interests.

Dr. Christoph Reinert reports that he does not have any relevant financial relationships with any commercial interests.

Dr. Istvan Szabolcs reports that he has received speaker honorarium from Berlin-Chemie AG, Genzyme Corporation, and Merck AG.

Dr. Martha A Zeiger reports that she does not have any relevant financial relationships with any commercial interests.

Dr. Michele Zini reports that she does not have any relevant financial relationships with any commercial interests.

REFERENCES

Note: All reference sources are followed by an evidence level (EL) rating of 1, 2, 3, or 4. The strongest evidence levels (EL 1 and EL 2) appear in red for easier recognition.

1. **Tunbridge WM, Evered DC, Hall R, et al.** The spectrum of thyroid disease in a community: The Wickham survey. *Clin Endocrinol (Oxf)*. 1977;7:481-493. [EL 2]
2. **Hegedüs L.** Clinical practice. The thyroid nodule. *N Engl J Med*. 2004;351:1764-1771. [EL 4—review]
3. **Ross DS.** Diagnostic approach to and treatment of thyroid nodules. I. In: Rose BD, ed. UpToDate. Wellesley, MA: UpToDate. Last accessed December 2008. [EL 4—review]
4. **Mortensen JD, Woolner LB, Bennett WA.** Gross and microscopic findings in clinically normal thyroid glands. *J Clin Endocrinol Metab*. 1955;15:1270-1280. [EL 3]

5. **Ezzat S, Sarti DA, Cain DR, Braunstein GD.** Thyroid incidentalomas: Prevalence by palpation and ultrasonography. *Arch Intern Med*. 1994;154:1838-1840. [EL 2]
6. **Tan GH, Gharib H.** Thyroid incidentalomas: Management approaches to nonpalpable nodules discovered incidentally on thyroid imaging. *Ann Intern Med*. 1997;126:226-231. [EL 4]
7. **Vander JB, Gaston EA, Dawber TR.** The significance of nontoxic thyroid nodules: Final report of a 15-year study of the incidence of thyroid malignancy. *Ann Intern Med*. 1968;69:537-540. [EL 3]
8. **Gharib H, Papini E.** Thyroid nodules: Clinical importance, assessment, and treatment. *Endocrinol Metab Clin North Am*. 2007;36:707-735. [EL 4—review]
9. **Rosai J, Carcangiu ML, DeLellis RA.** Tumors of the thyroid gland. Washington DC: Armed Forces Institute of Pathology, c1992. [EL 4]
10. **Belfiore A, Giuffrida D, La Rosa GL, et al.** High frequency of cancer in cold thyroid nodules occurring at young age. *Acta Endocrinol (Copenh)*. 1989;121:197-202. [EL 3]
11. **Aghini-Lombardi F, Antonangeli L, Martino E, et al.** The spectrum of thyroid disorders in an iodine-deficient community: The Pescopagano survey. *J Clin Endocrinol Metab*. 1999;84:561-566. [EL 2]
12. **Loh KC.** Familial nonmedullary thyroid carcinoma: A meta-review of case series. *Thyroid*. 1997;7:107-113. [EL 2]
13. **Punales MK, da Rocha AP, Meotti C, Gross JL, Maia AL.** Clinical and oncological features of children and young adults with multiple endocrine neoplasia type 2A. *Thyroid*. 2008;18:1261-1268. [EL 2]
14. **Rosenbaum MA, McHenry CR.** Contemporary management of papillary carcinoma of the thyroid gland. *Expert Rev Anticancer Ther*. 2009;9:317-329. [EL 4—review]
15. **Corrias A, Einaudi S, Chiorboli E, et al.** Accuracy of fine needle aspiration biopsy of thyroid nodules in detecting malignancy in childhood: Comparison with conventional clinical, laboratory, and imaging approaches. *J Clin Endocrinol Metab*. 2001;86:4644-4648. [EL 3]
16. **Gough J, Scott-Coombes D, Fausto Palazzo F.** Thyroid incidentaloma: An evidence-based assessment of management strategy. *World J Surg*. 2008;32:1264-1268. [EL 4]
17. **Christensen SB, Bondeson L, Ericsson UB, Lindholm K.** Prediction of malignancy in the solitary thyroid nodule by physical examination, thyroid scan, fine-needle biopsy and serum thyroglobulin: A prospective study of 100 surgically treated patients. *Acta Chir Scand*. 1984;150:433-439. [EL 3]
18. **Hamburger JI, Husain M.** Contribution of intraoperative pathology evaluation to surgical management of thyroid nodules. *Endocrinol Metab Clin North Am*. 1990;19:509-522. [EL 4]
19. **Hamming JF, Goslings BM, van Steenis GJ, van Ravenswaay Claasen H, Hermans J, van de Velde CJ.** The value of fine-needle aspiration biopsy in patients with nodular thyroid disease divided into groups of suspicion of malignant neoplasms on clinical grounds [erratum in: *Arch Intern Med* 1990;150:1088]. *Arch Intern Med*. 1990;150:113-116. [EL 3]
20. **Papini E.** The dilemma of non-palpable thyroid nodules. *J Endocrinol Invest*. 2003;26:3-4. [EL 4—editorial]
21. **Papini E, Guglielmi R, Bianchini A, et al.** Risk of malignancy in nonpalpable thyroid nodules: Predictive value of ultrasound and color-Doppler features. *J Clin Endocrinol Metab*. 2002;87:1941-1946. [EL 3]

22. Belfiore A, La Rosa GL, La Porta GA, et al. Cancer risk in patients with cold thyroid nodules: Relevance of iodine intake, sex, age, and multinodularity. *Am J Med.* 1992;93:363-369. [EL 3]
23. Tan GH, Gharib H, Reading CC. Solitary thyroid nodule: Comparison between palpation and ultrasonography. *Arch Intern Med.* 1995;155:2418-2423. [EL 3]
24. Jarlov AE, Nygaard B, Hegedus L, Hartling SG, Hansen JM. Observer variation in the clinical and laboratory evaluation of patients with thyroid dysfunction and goiter. *Thyroid.* 1998;8:393-398. [EL 3]
25. Boelaert K, Horacek J, Holder RL, Watkinson JC, Sheppard MC, Franklyn JA. Serum thyrotropin concentration as a novel predictor of malignancy in thyroid nodules investigated by fine-needle aspiration. *J Clin Endocrinol Metab.* 2006;91:4295-4301. [EL 3]
26. Ashcraft MW, Van Herle AJ. Management of thyroid nodules. II: Scanning techniques, thyroid suppressive therapy, and fine needle aspiration. *Head Neck Surg.* 1981;3:297-322. [EL 4—review]
27. Yano Y, Shibuya H, Kitagawa W, et al. Recent outcome of Graves' disease patients with papillary thyroid cancer. *Eur J Endocrinol.* 2007;157:325-329. [EL 3]
28. Shetty SK, Maher MM, Hahn PF, Halpern EF, Aquino SL. Significance of incidental thyroid lesions detected on CT: Correlation among CT, sonography, and pathology [erratum in: *AJR Am J Roentgenol.* 2007;188:8]. *AJR Am J Roentgenol.* 2006;187:1349-1356. [EL 3]
29. Razek AA, Sadek AG, Kombar OR, Elmahdy TE, Nada N. Role of apparent diffusion coefficient values in differentiation between malignant and benign solitary thyroid nodules. *AJNR Am J Neuroradiol.* 2008;29:563-568. [EL 3]
30. Are C, Hsu JF, Schoder H, Shah JP, Larson SM, Shaha AR. FDG-PET detected thyroid incidentalomas: need for further investigation? *Ann Surg Oncol.* 2007;14:239-247. [EL 3]
31. Choi JY, Lee KS, Kim HJ, et al. Focal thyroid lesions incidentally identified by integrated 18F-FDG PET/CT: Clinical significance and improved characterization. *J Nucl Med.* 2006;47:609-615. [EL 3]
32. Hurtado-Lopez LM, Arellano-Montano S, Torres-Acosta EM, et al. Combined use of fine-needle aspiration biopsy, MIBI scans and frozen section biopsy offers the best diagnostic accuracy in the assessment of the hypo-functioning solitary thyroid nodule. *Eur J Nucl Med Mol Imaging.* 2004;31:1273-1279. [EL 3]
33. Baskin HJ. Ultrasound of thyroid nodules. In: Baskin HJ, ed. *Thyroid Ultrasound and Ultrasound-Guided FNA Biopsy.* Boston, MA: Kluwer Academic Publishers, 2000: 71-86. [EL 4—review]
34. Solbiati L, Osti V, Cova L, Tonolini M. Ultrasound of thyroid, parathyroid glands and neck lymph nodes. *Eur Radiol.* 2001;11:2411-2424. [EL 4—review]
35. Ahuja A, Ying M. Sonography of neck lymph nodes. Part II: abnormal lymph nodes. *Clin Radiol.* 2003;58:359-366. [EL 4—review]
36. Frates MC, Benson CB, Doubilet PM, et al. Prevalence and distribution of carcinoma in patients with solitary and multiple thyroid nodules on sonography. *J Clin Endocrinol Metab.* 2006;91:3411-3417. [EL 3]
37. Mandel SJ. Diagnostic use of ultrasonography in patients with nodular thyroid disease. *Endocr Pract.* 2004;10:246-252. [EL 4—review]
38. Moon WJ, Jung SL, Lee JH, et al; Thyroid Study Group, Korean Society of Neuro- and Head and Neck Radiology. Benign and malignant thyroid nodules: US differentiation: Multicenter retrospective study. *Radiology.* 2008;247:762-770. [EL 3]
39. Kim EK, Park CS, Chung WY, et al. New sonographic criteria for recommending fine-needle aspiration biopsy of nonpalpable solid nodules of the thyroid. *AJR Am J Roentgenol.* 2002;178:687-691. [EL 2]
40. Cappelli C, Castellano M, Pirola I, et al. Thyroid nodule shape suggests malignancy. *Eur J Endocrinol.* 2006;155: 27-31. [EL 3]
41. Horvath E, Majlis S, Rossi R, et al. An ultrasonogram reporting system for thyroid nodules stratifying cancer risk for clinical management. *J Clin Endocrinol Metab.* 2009;94:1748-1751. [EL 2]
42. Campbell JP, Pillsbury HC 3rd. Management of the thyroid nodule. *Head Neck.* 1989;11:414-425. [EL 4]
43. Frasoldati A, Pesenti M, Gallo M, Caroggio A, Salvo D, Valcavi R. Diagnosis of neck recurrences in patients with differentiated thyroid carcinoma. *Cancer.* 2003;97:90-96. [EL 3]
44. Leenhardt L, Hejblum G, Franc B, et al. Indications and limits of ultrasound-guided cytology in the management of nonpalpable thyroid nodules. *J Clin Endocrinol Metab.* 1999;84:24-28. [EL 3]
45. Hagag P, Strauss S, Weiss M. Role of ultrasound-guided fine-needle aspiration biopsy in evaluation of nonpalpable thyroid nodules. *Thyroid.* 1998;8:989-995. [EL 3]
46. Cochand-Priollet B, Guillausseau PJ, Chagnon S, et al. The diagnostic value of fine-needle aspiration biopsy under ultrasonography in nonfunctional thyroid nodules: A prospective study comparing cytologic and histologic findings [erratum in: *Am J Med.* 1994;97:311]. *Am J Med.* 1994;97:152-157. [EL 3]
47. Roti E, degli Uberti EC, Bondanelli M, Braverman LE. Thyroid papillary microcarcinoma: A descriptive and meta-analysis study. *Eur J Endocrinol.* 2008;159:659-673. [EL 4—review]
48. Ito Y, Uruno T, Nakano K, et al. An observation trial without surgical treatment in patients with papillary microcarcinoma of the thyroid. *Thyroid.* 2003;13:381-387. [EL 3]
49. Verburg FA, Mader U, Luster M, Reiners C. Primary tumour diameter as a risk factor for advanced disease features of differentiated thyroid carcinoma. *Clin Endocrinol (Oxf).* 2009;71:291-297. [EL 3]
50. Asteria C, Giovanardi A, Pizzocaro A, et al. US-elastography in the differential diagnosis of benign and malignant thyroid nodules. *Thyroid.* 2008;18:523-531. [EL 2]
51. Tranquart F, Bleuzen A, Pierre-Renoult P, Chabrolle C, Sam Giau M, Lecomte P. Elastasonography of thyroid lesions [article in French]. *J Radiol.* 2008;89:35-39. [EL 3]
52. Rago T, Santini F, Scutari M, Pinchera A, Vitti P. Elastography: New developments in ultrasound for predicting malignancy in thyroid nodules. *J Clin Endocrinol Metab.* 2007;92:2917-2922. [EL 3]
53. Cosgrove D. Future prospects for SonoVue and CPS. *Eur Radiol.* 2004;14(Suppl 8):P116-P124. [EL 4]
54. Papini E, Bizzarri G, Pacella CM. Percutaneous laser ablation of benign and malignant thyroid nodules. *Curr Opin Endocrinol Diabetes Obes.* 2008;15:434-439. [EL 4—review]
55. Weber AL, Randolph G, Aksoy FG. The thyroid and parathyroid glands: CT and MR imaging and correlation with pathology and clinical findings. *Radiol Clin North Am.* 2000;38:1105-1129. [EL 4—review]
56. Wu HH, Jones JN, Osman J. Fine-needle aspiration cytology of the thyroid: Ten years experience in a community

- teaching hospital. *Diagn Cytopathol.* 2006;34:93-96. [EL 3]
57. DeMay RM. Thyroid. In: *The Art and Science of Cytopathology. Vol II: Aspiration Cytology.* Chicago, IL: ASCP Press, 1996: 703-778. [EL 4]
 58. Yang J, Schnadig V, Logrono R, Wasserman PG. Fine-needle aspiration of thyroid nodules: A study of 4703 patients with histologic and clinical correlations. *Cancer.* 2007;111:306-315. [EL 3]
 59. Danese D, Sciacchitano S, Farsetti A, Andreoli M, Pontecorvi A. Diagnostic accuracy of conventional versus sonography-guided fine-needle aspiration biopsy of thyroid nodules. *Thyroid.* 1998;8:15-21. [EL 4]
 60. Deandrea M, Mormile A, Veglio M, et al. Fine-needle aspiration biopsy of the thyroid: comparison between thyroid palpation and ultrasonography. *Endocr Pract.* 2002;8:282-286. [EL 3]
 61. Can AS, Peker K. Comparison of palpation-versus ultrasound-guided fine-needle aspiration biopsies in the evaluation of thyroid nodules. *BMC Res Notes.* 2008;1:12. [EL 4]
 62. British Thyroid Association. Guidelines for the management of thyroid cancer in adults. London: Royal College of Physicians of London and the British Thyroid Association, 2002 [cited December 1, 2005]. Available at: <http://www.british-thyroid-association.org/complete%20guidelines.pdf>. [EL 4—guidelines]
 63. European Federation of Cytology Societies. EFCS; 2007-2009. Fadda G. SIAPEC consensus review [written February 27, 2009; cited June 2009]. Available at: www.efes.eu. [EL 4—consensus]
 64. Baloch ZW, LiVolsi VA, Asa SL, et al. Diagnostic terminology and morphologic criteria for cytologic diagnosis of thyroid lesions: A synopsis of the National Cancer Institute Thyroid Fine-Needle Aspiration State of the Science Conference. *Diagn Cytopathol.* 2008;36:425-437. [EL 4—consensus]
 65. Redman R, Zalaznick H, Mazzaferri EL, Massoll NA. The impact of assessing specimen adequacy and number of needle passes for fine-needle aspiration biopsy of thyroid nodules. *Thyroid.* 2006;16:55-60. [EL 3]
 66. Kini SR. Specimen adequacy and assessment, reporting system. In: *Thyroid Cytopathology: An Atlas and Text.* Philadelphia, PA: Lippincott Williams & Wilkins, 2008: 17-26. [EL 4]
 67. Goellner JR, Gharib H, Grant CS, Johnson DA. Fine needle aspiration cytology of the thyroid, 1980 to 1986. *Acta Cytol.* 1987;31:587-590. [EL 3]
 68. Cersosimo E, Gharib H, Suman VJ, Goellner JR. "Suspicious" thyroid cytologic findings: outcome in patients without immediate surgical treatment. *Mayo Clin Proc.* 1993;68:343-348. [EL 3]
 69. Gharib H, Goellner JR. Fine-needle aspiration biopsy of thyroid nodules. *Endocr Pract.* 1995;1:410-417. [EL 4]
 70. Caruso D, Mazzaferri EL. Fine needle aspiration biopsy in the management of thyroid nodules. *Endocrinologist.* 1991;1:194-202. [EL 4]
 71. Hamberger B, Gharib H, Melton LJ 3rd, Goellner JR, Zinsmeister AR. Fine-needle aspiration biopsy of thyroid nodules: impact on thyroid practice and cost of care. *Am J Med.* 1982;73:381-384. [EL 3]
 72. Hamburger JL, Hamburger SW. Fine needle biopsy of thyroid nodules: avoiding the pitfalls. *N Y State J Med.* 1986;86:241-249. [EL 4]
 73. Pisani T, Bononi M, Nagar C, Angelini M, Bezzi M, Vecchione A. Fine needle aspiration and core needle biopsy techniques in the diagnosis of nodular thyroid pathologies. *Anticancer Res.* 2000;20:3843-3847. [EL 4]
 74. Renshaw AA, Pinnar N. Comparison of thyroid fine-needle aspiration and core needle biopsy. *Am J Clin Pathol.* 2007;128:370-374. [EL 3]
 75. Zhang S, Ivanovic M, Nemcek AA Jr, Defrias DV, Lucas E, Nayar R. Thin core needle biopsy crush preparations in conjunction with fine-needle aspiration for the evaluation of thyroid nodules: a complementary approach. *Cancer.* 2008;114:512-518. [EL 3]
 76. Elsheikh TM, Singh HK, Silverman JF. Fine-needle aspiration cytology versus core needle biopsy in the evaluation of thyroid and salivary gland lesions. *Path Case Rev.* 2007;12:3-9. [EL 4]
 77. Spencer CA, Takeuchi M, Kazarosyan M. Current status and performance goals for serum thyrotropin (TSH) assays. *Clin Chem.* 1996;42:140-145. [EL 4—review]
 78. Baloch Z, Carayon P, Conte-Devolx B, et al; Guidelines Committee, National Academy of Clinical Biochemistry. Laboratory medicine practice guidelines: Laboratory support for the diagnosis and monitoring of thyroid disease. *Thyroid.* 2003;13:3-126. [EL 4—guidelines]
 79. Ross DS. Laboratory assessment of thyroid dysfunction. In: Rose BD, ed. *UpToDate.* Wellesley, MA: UpToDate, 2005. [EL 4—review]
 80. Hegedus L, Bonnema SJ, Bennedbaek FN. Management of simple nodular goiter: Current status and future perspectives. *Endocr Rev.* 2003;24:102-132. [EL 4—review]
 81. Carle A, Pedersen IB, Knudsen N, et al. Thyroid volume in hypothyroidism due to autoimmune disease follows a unimodal distribution: Evidence against primary thyroid atrophy and autoimmune thyroiditis being distinct diseases. *J Clin Endocrinol Metab.* 2009;94:833-839. [EL 3]
 82. Wallaschofski H, Orda C, Georgi P, Miehle K, Paschke R. Distinction between autoimmune and non-autoimmune hyperthyroidism by determination of TSH-receptor antibodies in patients with the initial diagnosis of toxic multinodular goiter. *Horm Metab Res.* 2001;33:504-507. [EL 3]
 83. Pedersen IB, Knudsen N, Perrild H, Ovesen L, Laurberg P. TSH-receptor antibody measurement for differentiation of hyperthyroidism into Graves' disease and multinodular toxic goitre: A comparison of two competitive binding assays. *Clin Endocrinol (Oxf).* 2001;55:381-390. [EL 3]
 84. Date J, Feldt-Rasmussen U, Blichert-Toft M, Hegedus L, Graversen HP. Long-term observation of serum thyroglobulin after resection of nontoxic goiter and relation to ultrasonographically demonstrated relapse. *World J Surg.* 1996;20:351-356. [EL 3]
 85. Giovannella L, Ceriani L, Ghelfo A, Maffioli M, Keller F. Preoperative undetectable serum thyroglobulin in differentiated thyroid carcinoma: incidence, causes and management strategy. *Clin Endocrinol (Oxf).* 2007;67:547-551. [EL 3]
 86. Cohen R, Campos JM, Salaun C, et al; Groupe d'Etudes des Tumeurs a Calcitonine (GETC). Preoperative calcitonin levels are predictive of tumor size and postoperative calcitonin normalization in medullary thyroid carcinoma. *J Clin Endocrinol Metab.* 2000;85:919-922. [EL 3]
 87. Brandi ML, Gagel RF, Angeli A, et al. Guidelines for diagnosis and therapy of MEN type 1 and type 2. *J Clin Endocrinol Metab.* 2001;86:5658-5671. [EL 3—guidelines]
 88. Elisei R, Bottici V, Luchetti F, et al. Impact of routine measurement of serum calcitonin on the diagnosis and outcome of medullary thyroid cancer: Experience in 10,864 patients with nodular thyroid disorders. *J Clin Endocrinol Metab.* 2004;89:163-168. [EL 3]
 89. Vierhapper H, Raber W, Bieglmayer C, Kaserer K, Weinhausl A, Niederle B. Routine measurement of plasma

- calcitonin in nodular thyroid diseases. *J Clin Endocrinol Metab.* 1997;82:1589-1593. [EL 3]
90. **Cheung K, Roman SA, Wang TS, Walker HD, Sosa JA.** Calcitonin measurement in the evaluation of thyroid nodules in the United States: a cost-effectiveness and decision analysis. *J Clin Endocrinol Metab.* 2008;93:2173-2180. [EL 3]
 91. **Niccoli P, Wion-Barbot N, Caron P, et al; The French Medullary Study Group.** Interest of routine measurement of serum calcitonin: Study in a large series of thyroidectomized patients. *J Clin Endocrinol Metab.* 1997;82:338-341. [EL 3]
 92. **Costante G, Meringolo D, Durante C, Bianchi D, Nocera M, Tumino S, et al.** Predictive value of serum calcitonin levels for preoperative diagnosis of medullary thyroid carcinoma in a cohort of 5817 consecutive patients with thyroid nodules. *J Clin Endocrinol Metab.* 2007 Feb;92:450-455. [EL 2]
 93. **d'Herbomez M, Caron P, Bauters C, et al; French Group GTE (Groupe des Tumeurs Endocrines).** Reference range of serum calcitonin levels in humans: influence of calcitonin assays, sex, age, and cigarette smoking. *Eur J Endocrinol.* 2007;157:749-755. [EL 3]
 94. **Kotzmann H, Schmidt A, Scheuba C, et al.** Basal calcitonin levels and the response to pentagastrin stimulation in patients after kidney transplantation or on chronic hemodialysis as indicators of medullary carcinoma. *Thyroid.* 1999;9:943-947. [EL 3]
 95. **Erdogan MF, Gullu S, Baskal N, Uysal AR, Kamel N, Erdogan G.** Omeprazole: Calcitonin stimulation test for the diagnosis follow-up and family screening in medullary thyroid carcinoma. *J Clin Endocrinol Metab.* 1997;82:897-899. [EL 3]
 96. **Karges W, Dralle H, Raue F, et al; German Society for Endocrinology (DGE) - Thyroid Section.** Calcitonin measurement to detect medullary thyroid carcinoma in nodular goiter: German evidence-based consensus recommendation. *Exp Clin Endocrinol Diabetes.* 2004;112:52-58. [EL 3]
 97. **Doyle P, Duren C, Nerlich K, et al.** Potency and tolerance of calcitonin stimulation with high-dose calcium versus pentagastrin in normal adults [erratum in: *J Clin Endocrinol Metab.* 2009;94:4629]. *J Clin Endocrinol Metab.* 2009;94:2970-2974. [EL 2]
 98. **de Groot JW, Links TP, Plukker JT, Lips CJ, Hofstra RM.** RET as a diagnostic and therapeutic target in sporadic and hereditary endocrine tumors. *Endocr Rev.* 2006;27:535-560. [EL 4]
 99. **Wohllk N, Cote GJ, Bugalho MM, et al.** Relevance of RET proto-oncogene mutations in sporadic medullary thyroid carcinoma. *J Clin Endocrinol Metab.* 1996;81:3740-3745. [EL 3]
 100. **Meller J, Becker W.** The continuing importance of thyroid scintigraphy in the era of high-resolution ultrasound. *Eur J Nucl Med Mol Imaging.* 2002;29(Suppl 2):S425-S438. [EL 3]
 101. **Gharib H, Goellner JR.** Fine-needle aspiration biopsy of the thyroid: An appraisal. *Ann Intern Med.* 1993;118:282-289. [EL 4]
 102. **La Rosa GL, Belfiore A, Giuffrida D, et al.** Evaluation of the fine needle aspiration biopsy in the preoperative selection of cold thyroid nodules. *Cancer.* 1991;67:2137-2141. [EL 3]
 103. **Slowinska-Klencka D, Klencki M, Sporny S, Lewinski A.** Fine-needle aspiration biopsy of the thyroid in an area of endemic goitre: Influence of restored sufficient iodine supplementation on the clinical significance of cytological results. *Eur J Endocrinol.* 2002;146:19-26. [EL 3]
 104. **Knudsen N, Perrild H, Christiansen E, Rasmussen S, Dige-Petersen H, Jorgensen T.** Thyroid structure and size and two-year follow-up of solitary cold thyroid nodules in an unselected population with borderline iodine deficiency. *Eur J Endocrinol.* 2000;142:224-230. [EL 3]
 105. **Belfiore A, La Rosa GL, Padova G, Sava L, Ippolito O, Vigneri R.** The frequency of cold thyroid nodules and thyroid malignancies in patients from an iodine-deficient area. *Cancer.* 1987;15:60:3096-3102. [EL 3]
 106. **McHenry CR, Slusarczyk SJ, Askari AT, et al.** Refined use of scintigraphy in the evaluation of nodular thyroid disease. *Surgery.* 1998;124:656-661. [EL 3]
 107. **Meier DA, Kaplan MM.** Radioiodine uptake and thyroid scintiscanning. *Endocrinol Metab Clin North Am.* 2001;30:291-313. [EL 4—review]
 108. **Bonnema SJ, Bennedbaek FN, Hegedus L.** Danish endocrinologists' examination and treatment of non-toxic multinodular goiter: a questionnaire study [article in Danish]. *Ugeskr Laeger.* 2001;163:1265-1269. [EL 3]
 109. **Hillenrichs H, Emrich D.** Euthyroid goiter with and without functional autonomy in the euthyroid phase: a comparison [article in German]. *Nuklearmedizin.* 1998;37:95-100. [EL 3]
 110. **Tollin SR, Fallon EF, Mikhail M, Goldstein H, Yung E.** The utility of thyroid nuclear imaging and other studies in the detection and treatment of underlying thyroid abnormalities in patients with endogenous subclinical thyrotoxicosis. *Clin Nucl Med.* 2000;25:341-347. [EL 3]
 111. **Krohn K, Wohlgemuth S, Gerber H, Paschke R.** Hot microscopic areas of iodine-deficient euthyroid goitres contain constitutively activating TSH receptor mutations. *J Pathol.* 2000;192:37-42. [EL 3]
 112. **Kwak JY, Kim EK, Kim HJ, Kim MJ, Son EJ, Moon HJ.** How to combine ultrasound and cytological information in decision making about thyroid nodules. *Eur Radiol.* 2009;19:1923-1931. [EL 3]
 113. **McHenry CR, Walfish PG, Rosen IB.** Non-diagnostic fine needle aspiration biopsy: a dilemma in management of nodular thyroid disease. *Am Surg.* 1993;59:415-419. [EL 3]
 114. **Schmidt T, Riggs MW, Speights VO Jr.** Significance of nondiagnostic fine-needle aspiration of the thyroid. *South Med J.* 1997;90:1183-1186. [EL 3]
 115. **MacDonald L, Yazdi HM.** Nondiagnostic fine needle aspiration biopsy of the thyroid gland: a diagnostic dilemma. *Acta Cytol.* 1996;40:423-428. [EL 3]
 116. **Cappelli C, Pirola I, Castellano M, et al.** Fine needle cytology of complex thyroid nodules. *Eur J Endocrinol.* 2007;157:529-532. [EL 3]
 117. **Orlandi A, Puscar A, Capriata E, Fideleff H.** Repeated fine-needle aspiration of the thyroid in benign nodular thyroid disease: Critical evaluation of long-term follow-up. *Thyroid.* 2005;15:274-278. [EL 3]
 118. **Gallo M, Pesenti M, Valcavi R.** Ultrasound thyroid nodule measurements: the "gold standard" and its limitations in clinical decision making. *Endocr Pract.* 2003;9:194-199. [EL 4—review]
 119. **Menendez Torre E, Pineda Arribas J, Martinez de Esteban JP, et al.** Value of repeated fine needle aspiration cytology in patients with nodular goiter. *Acta Cytol.* 2007;51:850-852. [EL 3]
 120. **Gharib H, James EM, Charboneau JW, Naessens JM, Offord KP, Gorman CA.** Suppressive therapy with levothyroxine for solitary thyroid nodules: A double-blind

- controlled clinical study. *N Engl J Med.* 1987;317:70-75. [EL 1]
121. **La Rosa GL, Ippolito AM, Lupo L, et al.** Cold thyroid nodule reduction with L-thyroxine can be predicted by initial nodule volume and cytological characteristics. *J Clin Endocrinol Metab.* 1996;81:4385-4387. [EL 2]
 122. **Papini E, Petrucci L, Guglielmi R, et al.** Long-term changes in nodular goiter: a 5-year prospective randomized trial of levothyroxine suppressive therapy for benign cold thyroid nodules. *J Clin Endocrinol Metab.* 1998;83:780-783. [EL 1]
 123. **Wemeau JL, Caron P, Schwartz C, et al.** Effects of thyroid-stimulating hormone suppression with levothyroxine in reducing the volume of solitary thyroid nodules and improving extranodular nonpalpable changes: a randomized, double-blind, placebo-controlled trial by the French Thyroid Research Group. *J Clin Endocrinol Metab.* 2002;87:4928-4934. [EL 1]
 124. **Hegedus L, Nygaard B, Hansen JM.** Is routine thyroxine treatment to hinder postoperative recurrence of nontoxic goiter justified? *J Clin Endocrinol Metab.* 1999;84:756-760. [EL 2]
 125. **Moalem J, Suh I, Duh QY.** Treatment and prevention of recurrence of multinodular goiter: an evidence-based review of the literature. *World J Surg.* 2008;32:1301-1312. [EL 4]
 126. **Faber J, Galloe AM.** Changes in bone mass during prolonged subclinical hyperthyroidism due to L-thyroxine treatment: a meta-analysis. *Eur J Endocrinol.* 1994;130:350-356. [EL 1]
 127. **Uzzan B, Campos J, Cucherat M, Nony P, Boissel JP, Perret GY.** Effects on bone mass of long term treatment with thyroid hormones: A meta-analysis. *J Clin Endocrinol Metab.* 1996;81:4278-4289. [EL 1]
 128. **Sawin CT, Geller A, Wolf PA, et al.** Low serum thyrotropin concentrations as a risk factor for atrial fibrillation in older persons. *N Engl J Med.* 1994;331:1249-1252. [EL 2]
 129. **Parle JV, Maisonneuve P, Sheppard MC, Boyle P, Franklyn JA.** Prediction of all-cause and cardiovascular mortality in elderly people from one low serum thyrotropin result: A 10-year cohort study. *Lancet.* 2001;358:861-865. [EL 2]
 130. **La Rosa GL, Lupo L, Giuffrida D, Gullo D, Vigneri R, Belfiore A.** Levothyroxine and potassium iodide are both effective in treating benign solitary solid cold nodules of the thyroid. *Ann Intern Med.* 1995;122:1-8. [EL 2]
 131. **Miccoli P, Minuto MN, Ugolini C, Pisano R, Fosso A, Berti P.** Minimally invasive video-assisted thyroidectomy for benign thyroid disease: An evidence-based review. *World J Surg.* 2008;32:1333-1340. [EL 4—review]
 132. **Alvarado R, McMullen T, Sidhu SB, Delbridge LW, Sywak MS.** Minimally invasive thyroid surgery for single nodules: an evidence-based review of the lateral mini-incision technique. *World J Surg.* 2008;32:1341-1348. [EL 4—review]
 133. **Livraghi T, Paracchi A, Ferrari C, et al.** Treatment of autonomous thyroid nodules with percutaneous ethanol injection: preliminary results: work in progress. *Radiology.* 1990;175:827-829. [EL 4]
 134. **Pacella CM, Bizzarri G, Guglielmi R, et al.** Thyroid tissue: US-guided percutaneous interstitial laser ablation: a feasibility study. *Radiology.* 2000;217:673-677. [EL 3]
 135. **Verde G, Papini E, Pacella CM, et al.** Ultrasound guided percutaneous ethanol injection in the treatment of cystic thyroid nodules. *Clin Endocrinol (Oxf).* 1994;41:719-724. [EL 1]
 136. **Guglielmi R, Pacella CM, Bianchini A, et al.** Percutaneous ethanol injection treatment in benign thyroid lesions: role and efficacy. *Thyroid.* 2004;14:125-131. [EL 2]
 137. **Valcavi R, Frasoldati A.** Ultrasound-guided percutaneous ethanol injection therapy in thyroid cystic nodules. *Endocr Pract.* 2004;10:269-275. [EL 3]
 138. **Kim JH, Lee HK, Lee JH, Ahn IM, Choi CG.** Efficacy of sonographically guided percutaneous ethanol injection for treatment of thyroid cysts versus solid thyroid nodules. *AJR Am J Roentgenol.* 2003;180:1723-1726. [EL 3]
 139. **Zingrillo M, Torlontano M, Chiarella R, et al.** Percutaneous ethanol injection may be a definitive treatment for symptomatic thyroid cystic nodules not treatable by surgery: Five-year follow-up study. *Thyroid.* 1999;9:763-767. [EL 3]
 140. **Bennedbaek FN, Hegedus L.** Treatment of recurrent thyroid cysts with ethanol: A randomized double-blind controlled trial. *J Clin Endocrinol Metab.* 2003;88:5773-5777. [EL 1]
 141. **Lippi F, Ferrari C, Manetti L, et al; the Multicenter Study Group.** Treatment of solitary autonomous thyroid nodules by percutaneous ethanol injection: Results of an Italian multicenter study. *J Clin Endocrinol Metab.* 1996;81:3261-3264. [EL 3]
 142. **Livraghi T, Paracchi A, Ferrari C, Reschini E, Macchi RM, Bonifacino A.** Treatment of autonomous thyroid nodules with percutaneous ethanol injection: 4-year experience. *Radiology.* 1994;190:529-533. [EL 3]
 143. **Zingrillo M, Collura D, Ghigi MR, Nirchio V, Trischitta V.** Treatment of large cold benign thyroid nodules not eligible for surgery with percutaneous ethanol injection. *J Clin Endocrinol Metab.* 1998;83:3905-3907. [EL 3]
 144. **Bennedbaek FN, Nielsen LK, Hegedus L.** Effect of percutaneous ethanol injection therapy versus suppressive doses of L-thyroxine on benign solitary solid cold thyroid nodules: A randomized trial. *J Clin Endocrinol Metab.* 1998;83:830-835. [EL 1]
 145. **Kim YS, Rhim H, Tae K, Park DW, Kim ST.** Radiofrequency ablation of benign cold thyroid nodules: Initial clinical experience. *Thyroid.* 2006;16:361-367. [EL 4]
 146. **Spiezia S, Garberoglio R, Milone F, et al.** Thyroid nodules and related symptoms are stably controlled two years after radiofrequency thermal ablation. *Thyroid.* 2009;19:219-225. [EL 3]
 147. **Dossing H, Bennedbaek FN, Hegedus L.** Effect of ultrasound-guided interstitial laser photocoagulation on benign solitary solid cold thyroid nodules: One versus three treatments. *Thyroid.* 2006;16:763-768. [EL 3]
 148. **Dossing H, Bennedbaek FN, Hegedus L.** Effect of ultrasound-guided interstitial laser photocoagulation on benign solitary solid cold thyroid nodules: A randomised study. *Eur J Endocrinol.* 2005;152:341-345. [EL 2]
 149. **Papini E, Guglielmi R, Bizzarri G, et al.** Treatment of benign cold thyroid nodules: A randomized clinical trial of percutaneous laser ablation versus levothyroxine therapy or follow-up. *Thyroid.* 2007;17:229-235. [EL 1]
 150. **Cakir B, Ugras NS, Gul K, Ersoy R, Korukluoglu B.** Initial report of the results of percutaneous laser ablation of benign cold thyroid nodules: Evaluation of histopathological changes after 2 years. *Endocr Pathol.* 2009;20:170-176. [EL 3]
 151. **Meier DA, Brill DR, Becker DV, et al; Society of Nuclear Medicine.** Procedure guideline for therapy of thyroid disease with (131)iodine. *J Nucl Med.* 2002;43:856-861. [EL 3—guidelines]

152. Nygaard B, Hegedus L, Nielsen KG, Ulriksen P, Hansen JM. Long-term effect of radioactive iodine on thyroid function and size in patients with solitary autonomously functioning toxic thyroid nodules. *Clin Endocrinol (Oxf)*. 1999;50:197-202. [EL 3]
153. Dietlein M, Dressler J, Grunwald F, et al; Deutsche Gesellschaft für Nuklearmedizin. Guideline for radioiodine therapy for benign thyroid diseases (version 4) [article in German]. *Nuklearmedizin*. 2007;46:220-223. [EL 4—guidelines]
154. Reiners C, Schneider P. Radioiodine therapy of thyroid autonomy. *Eur J Nucl Med Mol Imaging*. 2002;29(Suppl 2):S471-S478. [EL 3]
155. Metso S, Jaatinen P, Huhtala H, Auvinen A, Oksala H, Salmi J. Increased cardiovascular and cancer mortality after radioiodine treatment for hyperthyroidism [erratum in: *J Clin Endocrinol Metab*. 2007;92:4008]. *J Clin Endocrinol Metab*. 2007;92:2190-2196. [EL 2]
156. Ron E, Doody MM, Becker DV, et al; Cooperative Thyrotoxicosis Therapy Follow-up Study Group. Cancer mortality following treatment for adult hyperthyroidism. *JAMA*. 1998;280:347-355. [EL 3]
157. Ceccarelli C, Bencivelli W, Vitti P, Grasso L, Pinchera A. Outcome of radioiodine-131 therapy in hyperfunctioning thyroid nodules: A 20 years' retrospective study. *Clin Endocrinol (Oxf)*. 2005;62:331-335. [EL 3]
158. Nygaard B, Faber J, Veje A, Hegedus L, Hansen JM. Transition of nodular toxic goiter to autoimmune hyperthyroidism triggered by 131I therapy. *Thyroid*. 1999;9:477-481. [EL 3]
159. Nygaard B, Knudsen JH, Hegedus L, Scient AV, Hansen JE. Thyrotropin receptor antibodies and Graves' disease, a side-effect of 131I treatment in patients with nontoxic goiter. *J Clin Endocrinol Metab*. 1997;82:2926-2930. [EL 3]
160. Wallaschofski H, Muller D, Georgi P, Paschke R. Induction of TSH-receptor antibodies in patients with toxic multinodular goitre by radioiodine treatment. *Horm Metab Res*. 2002;34:36-39. [EL 3]
161. Vos XG, Smit N, Enderdt E, Brosschot JF, Tijssen JG, Wiersinga WM. Age and stress as determinants of the severity of hyperthyroidism caused by Graves' disease in newly diagnosed patients. *Eur J Endocrinol*. 2009;160:193-199. [EL 3]
162. Bonnema SJ, Bennedbaek FN, Veje A, Marving J, Hegedus L. Propylthiouracil before 131I therapy of hyperthyroid diseases: effect on cure rate evaluated by a randomized clinical trial. *J Clin Endocrinol Metab*. 2004;89:4439-4444. [EL 2]
163. Walter MA, Briel M, Christ-Crain M, et al. Effects of antithyroid drugs on radioiodine treatment: systematic review and meta-analysis of randomised controlled trials. *BMJ*. 2007;334:514. [EL 1]
164. Weetman AP. Radioiodine treatment for benign thyroid diseases. *Clin Endocrinol (Oxf)*. 2007;66:757-764. [EL 4—review]
165. Hegedus L, Hansen BM, Knudsen N, Hansen JM. Reduction of size of thyroid with radioactive iodine in multinodular non-toxic goitre. *BMJ*. 1988;297:661-662. [EL 3]
166. Nygaard B, Hegedus L, Gervil M, Hjalgrim H, Soe-Jensen P, Hansen JM. Radioiodine treatment of multinodular non-toxic goitre. *BMJ*. 1993;307:828-832. [EL 3]
167. Huysmans DA, Hermus AR, Corstens FH, Barentsz JO, Kloppenborg PW. Large, compressive goiters treated with radioiodine. *Ann Intern Med*. 1994;121:757-762. [EL 3]
168. de Klerk JM, van Isselt JW, van Dijk A, et al. Iodine-131 therapy in sporadic nontoxic goiter. *J Nucl Med*. 1997;38:372-376. [EL 3]
169. Fast S, Nielsen VE, Bonnema SJ, Hegedus L. Time to reconsider nonsurgical therapy of benign non-toxic multinodular goitre: focus on recombinant human TSH augmented radioiodine therapy. *Eur J Endocrinol*. 2009;160:517-528. [EL 4—review]
170. Wesche MF, Tiel-V Buul MM, Lips P, Smits NJ, Wiersinga WM. A randomized trial comparing levothyroxine with radioactive iodine in the treatment of sporadic nontoxic goiter. *J Clin Endocrinol Metab*. 2001;86:998-1005. [EL 1]
171. Bonnema SJ, Bertelsen H, Mortensen J, et al. The feasibility of high dose iodine 131 treatment as an alternative to surgery in patients with a very large goiter: Effect on thyroid function and size and pulmonary function. *J Clin Endocrinol Metab*. 1999;84:3636-3641. [EL 4]
172. Jarlov AE, Hegedus L, Kristensen LO, Nygaard B, Hansen JM. Is calculation of the dose in radioiodine therapy of hyperthyroidism worth while? *Clin Endocrinol (Oxf)*. 1995;43:325-329. [EL 3]
173. Nielsen VE, Bonnema SJ, Hegedus L. The effects of recombinant human thyrotropin, in normal subjects and patients with goitre. *Clin Endocrinol (Oxf)*. 2004;61:655-663. [EL 4—review]
174. Nielsen VE, Bonnema SJ, Boel-Jorgensen H, Grupe P, Hegedus L. Stimulation with 0.3-mg recombinant human thyrotropin prior to iodine 131 therapy to improve the size reduction of benign nontoxic nodular goiter: a prospective randomized double-blind trial. *Arch Intern Med*. 2006;166:1476-1482. [EL 1]
175. Silva MN, Rubio IG, Romao R, et al. Administration of a single dose of recombinant human thyrotrophin enhances the efficacy of radioiodine treatment of large compressive multinodular goitres. *Clin Endocrinol (Oxf)*. 2004;60:300-308. [EL 3]
176. Nieuwlaat WA, Huysmans DA, van den Bosch HC, et al. Pretreatment with a single, low dose of recombinant human thyrotropin allows dose reduction of radioiodine therapy in patients with nodular goiter. *J Clin Endocrinol Metab*. 2003;88:3121-3129. [EL 3]
177. Barca MF, Gruppi C, Oliveira MT, et al. Cardiovascular assessment of hyperthyroid patients with multinodular goiter before and after radioiodine treatment preceded by stimulation with recombinant human TSH. *Endocrine*. 2007;32:175-181. [EL 3]
178. Nielsen VE, Bonnema SJ, Hegedus L. Transient goiter enlargement after administration of 0.3 mg of recombinant human thyrotropin in patients with benign nontoxic nodular goiter: a randomized, double-blind, crossover trial. *J Clin Endocrinol Metab*. 2006;91:1317-1322. [EL 1]
179. Pena S, Arum S, Cross M, et al. 123I thyroid uptake and thyroid size at 24, 48, and 72 hours after the administration of recombinant human thyroid-stimulating hormone to normal volunteers. *J Clin Endocrinol Metab*. 2006;91:506-510. [EL 3]
180. Castro MR, Gharib H. Continuing controversies in the management of thyroid nodules. *Ann Intern Med*. 2005;142:926-931. [EL 4]
181. Schlinkert RT, van Heerden JA, Goellner JR, et al. Factors that predict malignant thyroid lesions when fine-needle aspiration is "suspicious for follicular neoplasm." *Mayo Clin Proc*. 1997;72:913-916. [EL 3]
182. Bartolazzi A, Orlandi F, Saggiorato E, et al; Italian Thyroid Cancer Study Group (ITCSG). Galectin-3-expression analysis in the surgical selection of follicular thyroid nodules with indeterminate fine-needle aspiration cytology: a prospective multicentre study. *Lancet Oncol*. 2008;9:543-549. [EL 2]

183. Salvatore G, Giannini R, Faviana P, et al. Analysis of BRAF point mutation and RET/PTC rearrangement refines the fine-needle aspiration diagnosis of papillary thyroid carcinoma. *J Clin Endocrinol Metab.* 2004;89:5175-5180. [EL 2]
184. Yassa L, Cibas ES, Benson CB, et al. Long-term assessment of a multidisciplinary approach to thyroid nodule diagnostic evaluation. *Cancer.* 2007;111:508-516. [EL 2]
185. Haymart MR, Greenblatt DY, Elson DF, Chen H. The role of intraoperative frozen section if suspicious for papillary thyroid cancer. *Thyroid.* 2008;18:419-423. [EL 3]
186. Cobin RH, Gharib H, Bergman DA, et al; **Thyroid Carcinoma Task Force.** AACE/AAES medical/surgical guidelines for clinical practice: Management of thyroid carcinoma [erratum in: *Endocr Pract.* 2008;14:802-803]. *Endocr Pract.* 2001;7:202-220. [EL 4—guidelines]
187. Cooper DS, Doherty GM, Haugen BR, et al; **American Thyroid Association Guidelines Taskforce.** Management guidelines for patients with thyroid nodules and differentiated thyroid cancer. *Thyroid.* 2006;16:109-142. [EL 4—guidelines]
188. Pacini F, Schlumberger M, Dralle H, Elisei R, Smit JW, Wiersinga W; **European Thyroid Cancer Taskforce.** European consensus for the management of patients with differentiated thyroid carcinoma of the follicular epithelium [erratum in: *Eur J Endocrinol.* 2006;155:385]. *Eur J Endocrinol.* 2006;154:787-803. [EL 4—consensus]
189. **National Comprehensive Cancer Network.** NCCN categories of evidence and consensus [cited March 2009]. Available at: http://www.nccn.org/professionals/physician_gls/categories_of_consensus.asp. [EL 4—guidelines]
190. Baloch ZW, Barroeta JE, Walsh J, et al. Utility of thyroglobulin measurement in fine-needle aspiration biopsy specimens of lymph nodes in the diagnosis of recurrent thyroid carcinoma. *Cytojournal.* 2008;5:1. [EL 4]
191. Kim E, Park JS, Son KR, Kim JH, Jeon SJ, Na DG. Preoperative diagnosis of cervical metastatic lymph nodes in papillary thyroid carcinoma: Comparison of ultrasound, computed tomography, and combined ultrasound with computed tomography. *Thyroid.* 2008;18:411-418. [EL 3]
192. Freudenberg LS, Antoch G, Jentzen W, et al. Value of (124)I-PET/CT in staging of patients with differentiated thyroid cancer. *Eur Radiol.* 2004;14:2092-2098. [EL 3]
193. Abalovich M, Amino N, Barbour LA, et al. Management of thyroid dysfunction during pregnancy and postpartum: An Endocrine Society Clinical Practice Guideline. *J Clin Endocrinol Metab.* 2007;92(Suppl 8):S1-S47. [EL 4—guidelines]
194. Kung AW, Chau MT, Lao TT, Tam SC, Low LC. The effect of pregnancy on thyroid nodule formation. *J Clin Endocrinol Metab.* 2002;87:1010-1014. [EL 2]
195. Rosen IB, Korman M, Walfish PG. Thyroid nodular disease in pregnancy: Current diagnosis and management. *Clin Obstet Gynecol.* 1997;40:81-89. [EL 4]
196. Marley EF, Oertel YC. Fine-needle aspiration of thyroid lesions in 57 pregnant and postpartum women. *Diagn Cytopathol.* 1997;16:122-125. [EL 3]
197. Moosa M, Mazzaferri EL. Outcome of differentiated thyroid cancer diagnosed in pregnant women. *J Clin Endocrinol Metab.* 1997;82:2862-2866. [EL 3]
198. Rallison ML, Dobyns BM, Keating FR Jr, Rall JE, Tyler FH. Thyroid nodularity in children. *JAMA.* 1975;233:1069-1072. [EL 4]
199. Hung W. Nodular thyroid disease and thyroid carcinoma. *Pediatr Ann.* 1992;21:50-57. [EL 4—review]
200. Niedziela M. Pathogenesis, diagnosis and management of thyroid nodules in children. *Endocr Relat Cancer.* 2006;13:427-453. [EL 4—review]
201. Raab SS, Silverman JF, Elsheikh TM, Thomas PA, Wakely PE. Pediatric thyroid nodules: Disease demographics and clinical management as determined by fine needle aspiration biopsy. *Pediatrics.* 1995;95:46-49. [EL 3]
202. Amrikachi M, Ponder TB, Wheeler TM, Smith D, Ramzy I. Thyroid fine-needle aspiration biopsy in children and adolescents: experience with 218 aspirates. *Diagn Cytopathol.* 2005;32:189-192. [EL 3]
203. Chang SH, Joo M, Kim H. Fine needle aspiration biopsy of thyroid nodules in children and adolescents. *J Korean Med Sci.* 2006;21:469-473. [EL 3]
204. Belfiore A, La Rosa GL, Padova G, Sava L, Ippolito O, Vigneri R. The frequency of cold thyroid nodules and thyroid malignancies in patients from an iodine-deficient area. *Cancer.* 1987;60:3096-3102. [EL 3]
205. **Canadian Pediatric Thyroid Nodule (CaPTN) Study Group.** The Canadian Pediatric Thyroid Nodule Study: An evaluation of current management practices. *J Pediatr Surg.* 2008;43:826-830. [EL 4]
206. Drozd VM, Lushchik ML, Polyanskaya ON, et al. The usual ultrasonographic features of thyroid cancer are less frequent in small tumors that develop after a long latent period after the Chernobyl radiation release accident. *Thyroid.* 2009;19:725-734. [EL 2]
207. Feinmesser R, Lubin E, Segal K, Noyek A. Carcinoma of the thyroid in children: A review. *J Pediatr Endocrinol Metab.* 1997;10:561-568. [EL 4—review]
208. Alessandri AJ, Goddard KJ, Blair GK, Fryer CJ, Schultz KR. Age is the major determinant of recurrence in pediatric differentiated thyroid carcinoma. *Med Pediatr Oncol.* 2000;35:41-46. [EL 3]
209. Niedziela M, Breborowicz D, Trejster E, Korman E. Hot nodules in children and adolescents in western Poland from 1996 to 2000: Clinical analysis of 31 patients. *J Pediatr Endocrinol Metab.* 2002;15:823-830. [EL 3]
210. Haynes RB, Wilczynski N, McKibbin KA, Walker CJ, Sinclair JC. Developing optimal search strategies for detecting clinically sound studies in MEDLINE. *J Am Med Assoc.* 1994;1:447-458. [EL 4]
211. Hunt DL, McKibbin KA. Locating and appraising systematic reviews. *Ann Intern Med.* 1997;126:532-538. [EL 4]
212. **Mechanick JI, Bergman DA, Braithwaite SS, Palumbo PJ; American Association of Clinical Endocrinologists Ad Hoc Task Force for Standardized Production of Clinical Practice Guidelines.** American Association of Clinical Endocrinologists protocol for standardized production of clinical practice guidelines [erratum in: *Endocr Pract.* 2008;14:802-803]. *Endocr Pract.* 2004;10:353-361. [EL 4—guidelines]
213. **Mechanick JI, Kushner RF, Sugerman HJ, et al.** American Association of Clinical Endocrinologists, The Obesity Society, and American Society for Metabolic & Bariatric Surgery Medical guidelines for clinical practice for the perioperative nutritional, metabolic, and nonsurgical support of the bariatric surgery patient. *Endocr Pract.* 2008;14(Suppl 1):1-83. [EL 4—guidelines]
214. Gharib H, Papini E, Paschke R. Thyroid nodules: A review of current guidelines, practices, and prospects. *Eur J Endocrinol.* 2008;159:493-505. [EL 4—review]